La-Net

OBG 507

GYNAECOLOGICAL CLINIC AND SIMULATION TRAINING

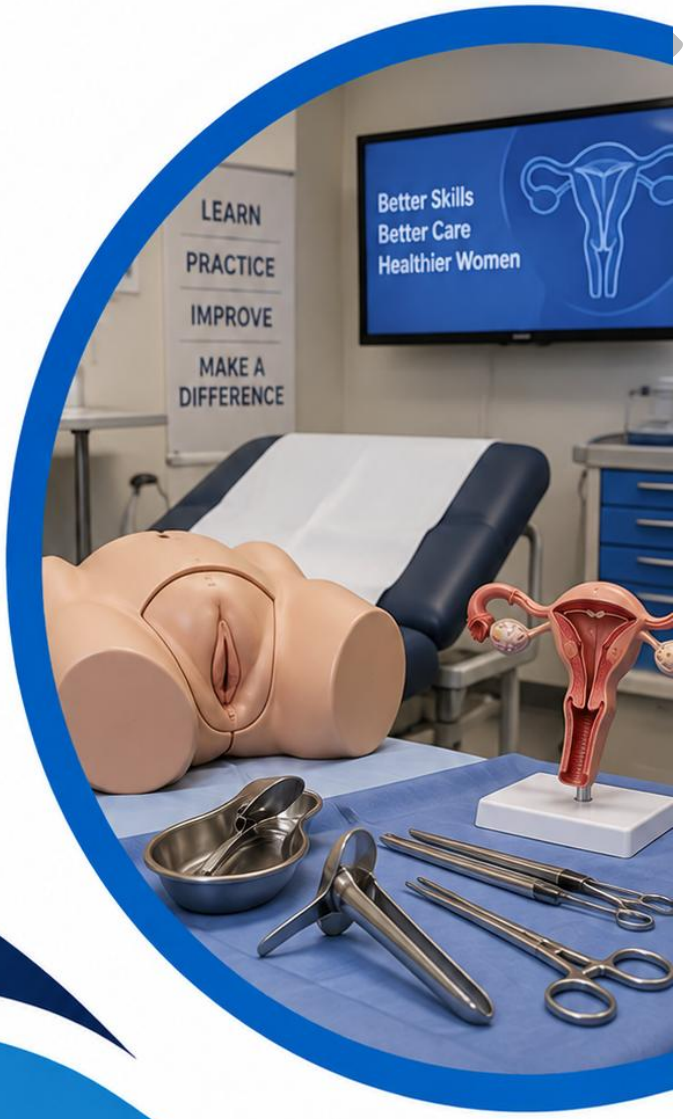

Download on the App Store

GET IT ON Google Play

Course video is available on our app

lanetonline.com

Course code: OBG 507

Course title: Gynaecological Clinic and Simulation Training

Course credit load: 2 Units

Series 1: Approach to the Gynaecological Patient

- **Part 1.1: Principles of the Gynaecological Consultation**
    - Sub Part 1.1.1: Structure and goals of the gynaecological consultation
    - Sub Part 1.1.2: Communication skills in the gynaecological clinic
    - Sub Part 1.1.3: Building rapport and trust with the gynaecological patient
- **Part 1.2: Professionalism, Consent, and Chaperoning**
    - Sub Part 1.2.1: Professional conduct in the gynaecological clinic
    - Sub Part 1.2.2: Informed consent in gynaecological consultation
    - Sub Part 1.2.3: Chaperoning and safeguarding dignity
- **Part 1.3: Cultural Sensitivity and Special Considerations**
    - Sub Part 1.3.1: Cultural and religious sensitivity in gynaecological practice
    - Sub Part 1.3.2: Approaching the adolescent gynaecological patient
    - Sub Part 1.3.3: Approaching patients with additional communication needs
- **Part 1.4: The Clinic Environment and Workflow**
    - Sub Part 1.4.1: Organising the gynaecological clinic environment
    - Sub Part 1.4.2: Clinic workflow and time management
    - Sub Part 1.4.3: Simulation-based training in gynaecological clinical skills

Introduction

Picture a young woman walking into a gynaecology clinic for the first time, uncertain, perhaps anxious, about what will be asked of her and what the examination will involve. How she is greeted, spoken to, and treated in those first few minutes will shape not only this consultation but her willingness to seek gynaecological care again in the future. This Series lays the essential foundation for the whole of this course: how to approach the gynaecological patient with genuine

la-NET | ONLINE LEARNING VIDEO PLATFORM FOR POST-SECONDARY & HIGHER INSTITUTION STUDENTS

lanetonline.com

professionalism, sensitivity, and skill, and how simulation-based training helps you develop that approach safely before you meet your first real patient.

The aim of this Series is to equip you with the knowledge and attitudes required to approach the gynaecological patient professionally, sensitively, and effectively, and to understand the role of simulation-based training in developing these skills.

We shall commence this Series by examining the principles and structure of the gynaecological consultation, including effective communication. Next, we will consider professionalism, informed consent, and chaperoning. Following that, our attention turns to cultural sensitivity and special considerations for diverse patient groups. Finally, we will conclude by examining the gynaecological clinic environment, workflow, and the role of simulation-based training in developing clinical skills.

Series Learning Outcomes

Upon completing this Series, you should be able to:

- **SLO 1.1:** demonstrate the structured approach and goals of the gynaecological consultation,
- **SLO 1.2:** describe effective communication skills in the gynaecological clinic,
- **SLO 1.3:** describe the principles of professionalism, informed consent, and chaperoning,
- **SLO 1.4:** describe cultural sensitivity and special considerations in approaching the gynaecological patient,
- **SLO 1.5:** describe how to organise the gynaecological clinic environment and workflow, and
- **SLO 1.6:** describe the role of simulation-based training in developing gynaecological clinical skills.

1.1 Principles of the Gynaecological Consultation

1.1.1 Structure and goals of the gynaecological consultation

A well-structured gynaecological consultation typically progresses through a series of recognisable stages, beginning with introduction and establishing the reason for attendance, followed by history taking, examination where indicated, discussion of findings and management options, and a clear plan for follow-up or further investigation, with each stage building logically on the one before it rather than proceeding in an ad hoc or disorganised fashion that risks missing important information or leaving the woman confused about what happens next.

laNET | ONLINE LEARNING VIDEO PLATFORM FOR POST-SECONDARY & HIGHER INSTITUTION STUDENTS

lanetonline.com

The overarching goals of any gynaecological consultation extend beyond simply reaching a diagnosis, encompassing genuine understanding of the impact of symptoms on the woman's quality of life, shared decision-making that respects her values and preferences, and ensuring she leaves the consultation with a clear understanding of what has been found, what will happen next, and when and how to seek further help if needed, all of which together determine whether a consultation was genuinely successful, not merely clinically accurate.

Fill in the blank: A well-structured gynaecological consultation begins with introduction and establishing the reason for _____. The goals of consultation include shared _____ that respects the woman's values and preferences.

1.1.2 Communication skills in the gynaecological clinic

Effective communication in the gynaecological clinic relies on open questioning at the outset of the consultation, allowing the woman to describe her concerns in her own words before narrowing to more specific, closed questions, active listening (demonstrated through appropriate eye contact, minimal interruption, and reflecting back what has been heard), and the use of clear, jargon-free language that a woman without medical training can genuinely understand and act upon.

Non-verbal communication is equally important, with a calm, unhurried manner, appropriate body language, and genuine attentiveness conveying respect and care even before a word is spoken, while awareness of the woman's own non-verbal cues, hesitation, discomfort, or reluctance to elaborate on a particular topic, can alert the clinician to sensitive areas requiring a more gentle, patient approach rather than direct, potentially distressing questioning.

Fill in the blank: Effective communication begins with _____ questioning, allowing the woman to describe her concerns in her own words. Non-verbal communication conveys respect and care even before a _____ is spoken.

1.1.3 Building rapport and trust with the gynaecological patient

Rapport and trust are foundational to effective gynaecological care, given the frequently sensitive, intimate nature of the symptoms and examinations involved, built through consistency, genuine warmth, and demonstrable respect for the woman's autonomy and dignity from the very first moment of contact, whether that first contact is a receptionist, a nurse, or the consulting clinician themselves.

A woman who trusts her clinician is considerably more likely to disclose sensitive or embarrassing symptoms accurately and completely, to engage genuinely with recommended investigations and treatment, and to return for necessary follow-up care, meaning that time invested in building rapport at an early stage of the relationship is never wasted time, but rather a genuinely essential clinical investment that directly supports the accuracy and effectiveness of everything that follows.

lantonline.com

Fill in the blank: Rapport and trust are built through consistency, genuine warmth, and demonstrable respect for the woman's _____ and dignity. A woman who trusts her clinician is more likely to disclose sensitive symptoms _____ and completely.

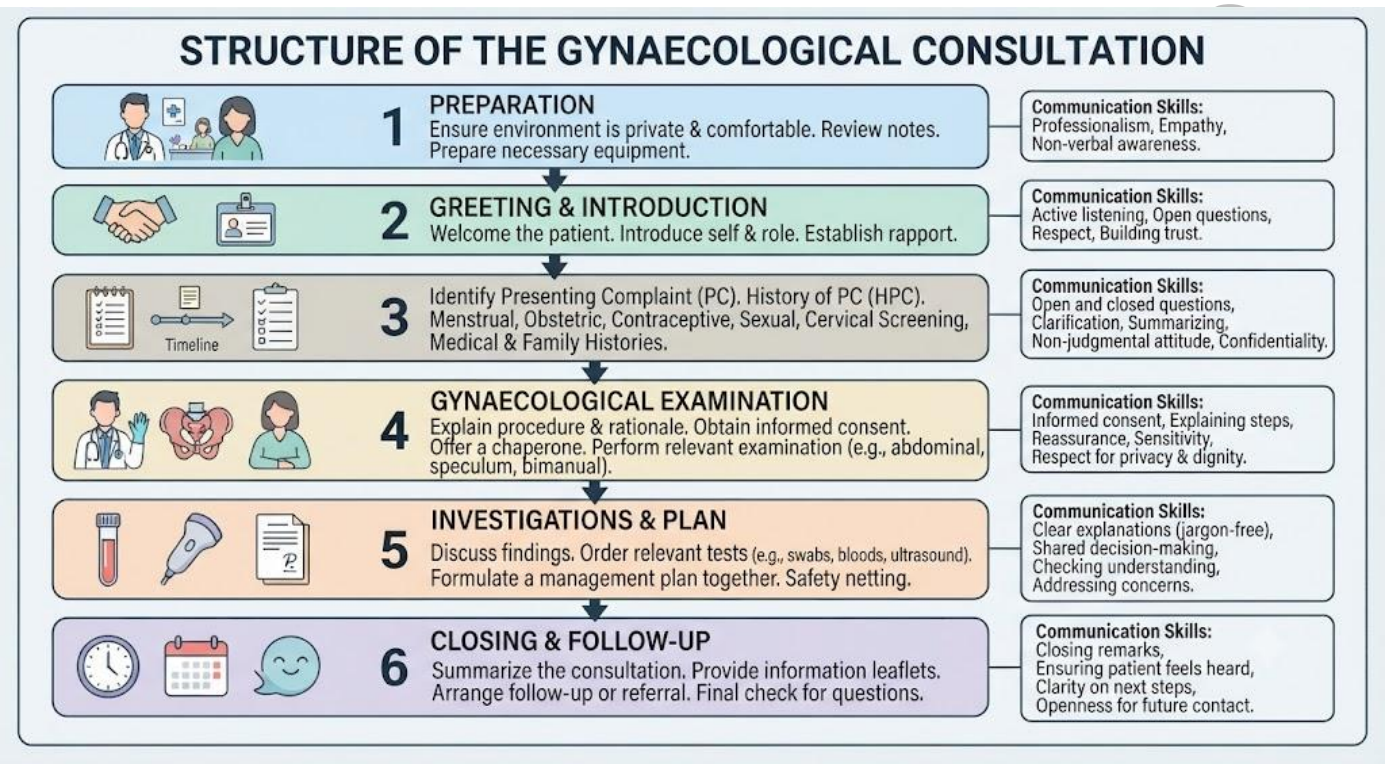

Figure 1.1: The structured stages of a gynaecological consultation.

Pilot questions 1.1

1. Describe the sequential stages of a well-structured gynaecological consultation. (Linked to SLO 1.1)
2. Explain the goals of a gynaecological consultation beyond reaching a diagnosis. (Linked to SLO 1.1)
3. Describe the principles of effective verbal communication in the gynaecological clinic. (Linked to SLO 1.2)
4. Explain the role of non-verbal communication in the gynaecological consultation. (Linked to SLO 1.2)
5. Explain why building rapport and trust is a genuine clinical investment. (Linked to SLO 1.2)

1.2 Professionalism, Consent, and Chaperoning

1.2.1 Professional conduct in the gynaecological clinic

Professional conduct in the gynaecological clinic encompasses appropriate dress and personal presentation, punctuality and respect for the woman's time, maintaining strict confidentiality of all information shared, and consistently treating every woman with courtesy and respect regardless of her background, presenting complaint, or personal circumstances, standards that apply equally whether the clinician is a student, trainee, or senior consultant.

Maintaining appropriate professional boundaries throughout the clinical relationship, avoiding any behaviour that could reasonably be perceived as inappropriate given the intimate nature of gynaecological practice, and recognising and appropriately managing one's own personal reactions or discomfort with certain topics or presentations, are all essential components of professionalism specific to this particular area of clinical practice, distinguishing genuinely professional conduct from mere technical competence alone.

Fill in the blank: Professional conduct includes appropriate dress, punctuality, and maintaining strict _____ of all information shared. Maintaining appropriate professional _____ throughout the clinical relationship is essential given the intimate nature of gynaecological practice.

1.2.2 Informed consent in gynaecological consultation

Informed consent for any gynaecological examination or procedure requires a clear explanation of what is being proposed, why it is being recommended, what it will involve, and any reasonable alternatives, including the option to decline, delivered before the examination or procedure begins and in language the woman can genuinely understand, rather than as a hurried formality completed simply to satisfy a documentation requirement.

Consent must be given voluntarily and can be withdrawn by the woman at any point, even during an examination already in progress, with the clinician stopping immediately if asked to do so, and it is worth explicitly reinforcing to the woman, particularly at a first consultation, that she remains in control throughout and that declining any part of the assessment will not compromise the quality or continuity of her ongoing care.

Fill in the blank: Informed consent requires explanation of what is proposed, why it is recommended, and any reasonable _____. Consent can be withdrawn by the woman at any point, even during an examination already in _____.

1.2.3 Chaperoning and safeguarding dignity

A chaperone (an independent observer present during an intimate examination) should be offered to every woman undergoing a gynaecological examination, regardless of the gender of the examining clinician, with the specific role, identity, and presence of the chaperone clearly explained beforehand, and the woman's preference, whether to have a chaperone present, to decline one, or to request a specific individual, respected wherever clinically and practically possible.

lanetonline.com

Safeguarding a woman's dignity throughout any gynaecological examination extends well beyond the presence of a chaperone alone, encompassing adequate privacy for undressing and dressing, appropriate draping during the examination itself, clear explanation of each step immediately before it is performed, and, throughout, an unhurried, respectful manner that consistently reflects genuine care for the woman as a person rather than treating the examination as a purely mechanical, transactional clinical task.

Fill in the blank: A chaperone should be offered to every woman undergoing a gynaecological examination, regardless of examiner _____. Safeguarding dignity includes adequate privacy, appropriate draping, and clear explanation of each _____.

Element	Key Details
Information Disclosure	Explain diagnosis, procedure, risks, benefits, and alternatives in clear language.
Voluntary Decision	Ensure the patient's choice is free from coercion or undue influence.
Capacity and Understanding	Confirm the patient has capacity and comprehends the information provided.
Documentation	Record consent clearly in medical notes or formal consent forms.
Chaperone Presence	Offer a trained chaperone during intimate examinations.
Professional Boundaries	Maintain dignity, privacy, and respect throughout the consultation.
Patient Comfort	Provide reassurance, explain each step, and respond to concerns promptly.

Box 1.2: Checklist for informed consent and chaperoning in gynaecological practice.

Pilot questions 1.2

1. Describe the components of professional conduct in the gynaecological clinic. (Linked to SLO 1.3)
2. Explain the importance of maintaining professional boundaries in gynaecological practice. (Linked to SLO 1.3)
3. Describe the components of valid informed consent for a gynaecological examination. (Linked to SLO 1.3)
4. Explain why consent can be withdrawn at any point during an examination. (Linked to SLO 1.3)
5. Describe the role of a chaperone and other measures that safeguard a woman's dignity during examination. (Linked to SLO 1.3)

1.3 Cultural Sensitivity and Special Considerations

lanetonline.com

1.3.1 Cultural and religious sensitivity in gynaecological practice

Cultural and religious beliefs can significantly influence a woman's comfort discussing gynaecological symptoms, her preferences around the gender of her examiner, and her attitudes towards specific investigations or treatments, and a genuinely respectful, individualised approach, asking about and accommodating these preferences wherever reasonably possible, rather than applying a rigid, uniform approach to every consultation, meaningfully improves both the woman's experience and her engagement with recommended care.

In the diverse Nigerian context specifically clinicians should be aware of the wide range of cultural and religious perspectives their patients may hold regarding menstruation, fertility, contraception, and gynaecological examination, approaching each woman as an individual rather than assuming a particular set of beliefs based on apparent ethnicity, religion, or region, while remaining sensitively aware of common patterns that may genuinely inform a more attuned, contextually appropriate approach to a given consultation.

Fill in the blank: Cultural and religious beliefs can significantly influence a woman's comfort discussing symptoms and her preferences around examiner _____. Clinicians should approach each woman as an _____ rather than assuming beliefs based on apparent background.

1.3.2 Approaching the adolescent gynaecological patient

Adolescent patients require a particular, adapted approach, balancing the young woman's own developing autonomy and right to confidentiality with the appropriate involvement of a parent or guardian, generally guided by an assessment of the individual adolescent's maturity and understanding, alongside relevant local legal and professional guidance on consent and confidentiality for this specific age group.

Building trust with an adolescent patient often requires offering, wherever appropriate and safe, an opportunity to speak with the clinician alone for at least part of the consultation, using age-appropriate, non-judgemental language, and being explicit and honest about the specific limits of confidentiality, particularly where there are safeguarding concerns that would need to be escalated regardless of the adolescent's own preference for the information to remain confidential.

Fill in the blank: The approach to an adolescent patient balances developing autonomy with appropriate parental or guardian _____. Building trust often requires offering an opportunity to speak with the clinician _____ for at least part of the consultation.

1.3.3 Approaching patients with additional communication needs

Women with additional communication needs (including hearing or visual impairment, learning disability, or limited literacy) require specific, deliberate adaptation of the standard consultation approach, potentially including the use of a professional interpreter or communication support worker, written or pictorial information provided in an accessible

la-NET | ONLINE LEARNING VIDEO PLATFORM FOR POST-SECONDARY & HIGHER INSTITUTION STUDENTS

format, and allowing additional time for the consultation to ensure genuine, effective communication and comprehension rather than merely the appearance of it.

Language barriers specifically should be addressed using a professional interpreter wherever possible, rather than relying on a family member, particularly for sensitive gynaecological content, given the risk that a family member may filter, alter, or feel uncomfortable relaying sensitive information accurately, potentially compromising both the accuracy of the history obtained and the woman's genuine privacy and autonomy in the consultation.

Fill in the blank: Language barriers should be addressed using a professional _____ wherever possible, rather than relying on a family member. A family member may filter or feel uncomfortable relaying sensitive _____ accurately.

Patient Group	Key Adaptation
Adolescents	Provide age-appropriate explanations, ensure confidentiality, and involve guardians only when necessary.
Patients with Language Barriers	Use professional interpreters, avoid relying on family members, provide translated materials.
Patients with Disabilities	Ensure accessible facilities, adapt communication methods, allow extra time, involve caregivers when appropriate.
Patients from Diverse Cultural Backgrounds	Show cultural sensitivity, respect beliefs and practices, avoid assumptions, and seek consent carefully.

Table 1.3: Special considerations and adaptations for diverse patient groups in gynaecological practice.

Pilot questions 1.3

1. Explain how cultural and religious beliefs can influence a gynaecological consultation. (Linked to SLO 1.4)
2. Describe an appropriate approach to cultural sensitivity in the diverse Nigerian context. (Linked to SLO 1.4)
3. Describe the approach to consultation with an adolescent gynaecological patient. (Linked to SLO 1.4)
4. Explain the limits of confidentiality that should be made explicit to an adolescent patient. (Linked to SLO 1.4)
5. Describe the adaptations required for patients with additional communication needs. (Linked to SLO 1.4)

1.4 The Clinic Environment and Workflow

lanetonline.com

1.4.1 Organising the gynaecological clinic environment

A well-organised gynaecological clinic environment ensures adequate privacy for both consultation and examination, with soundproofing or sufficient separation to prevent conversations being overheard, appropriately equipped examination rooms with all necessary equipment readily available and in good working order, and a comfortable, welcoming waiting area, all of which together meaningfully influence a woman's willingness to attend and to disclose sensitive information openly once she does.

Practical environmental considerations also include ensuring examination couches and equipment are appropriately positioned to preserve the woman's dignity during any necessary transition into an examination position, adequate lighting for accurate clinical assessment, and immediate availability of appropriate personal protective equipment and infection control measures, reflecting the genuinely practical, operational dimension of delivering consistently high-quality gynaecological care.

Fill in the blank: A well-organised clinic environment ensures adequate privacy, appropriately equipped examination rooms, and a comfortable, welcoming waiting _____. Environmental considerations also include ensuring adequate _____ for accurate clinical assessment.

1.4.2 Clinic workflow and time management

Efficient clinic workflow balances the competing demands of thoroughness and time management, with a realistic, appropriately allocated appointment schedule that recognises some consultations, particularly those involving a first presentation, complex history, or significant emotional content, will genuinely require more time than a routine, straightforward follow-up visit, rather than treating every appointment slot as functionally interchangeable regardless of its actual clinical complexity.

Effective time management within an individual consultation involves structuring the encounter efficiently without making the woman feel rushed, prioritising the most clinically important elements of history and examination when time is genuinely constrained, and being transparent with the woman about time constraints where relevant, offering a further appointment to complete an assessment rather than compromising its quality or her sense of being genuinely heard within an inadequate timeframe.

Fill in the blank: Efficient clinic workflow recognises that some consultations require more _____ than a routine follow-up visit. Effective time management involves structuring the encounter efficiently without making the woman feel _____.

1.4.3 Simulation-based training in gynaecological clinical skills

Simulation-based training using manikins, standardised or simulated patients, and structured scenarios allows deliberate, repeated practice of gynaecological history taking, examination technique, communication skills, and procedural competencies in a safe, controlled environment

la-net.com

before these skills are applied in genuine clinical practice, offering learners the valuable opportunity to make and learn from mistakes without any risk of harm to an actual patient.

Structured feedback following simulation (from faculty, peers, or, where used, standardised patients themselves) is essential to translate simulated practice into genuine improvement in real clinical performance, with effective simulation training programmes deliberately incorporating this feedback, together with the opportunity for repeated deliberate practice, as core structural components rather than treating simulation as a single, one-off exercise disconnected from the ongoing longitudinal process of developing genuine clinical competence.

Fill in the blank: Simulation-based training allows deliberate, repeated practice in a safe, controlled environment without risk of _____ to an actual patient. Structured _____ following simulation is essential to translate practice into genuine improvement in clinical performance.

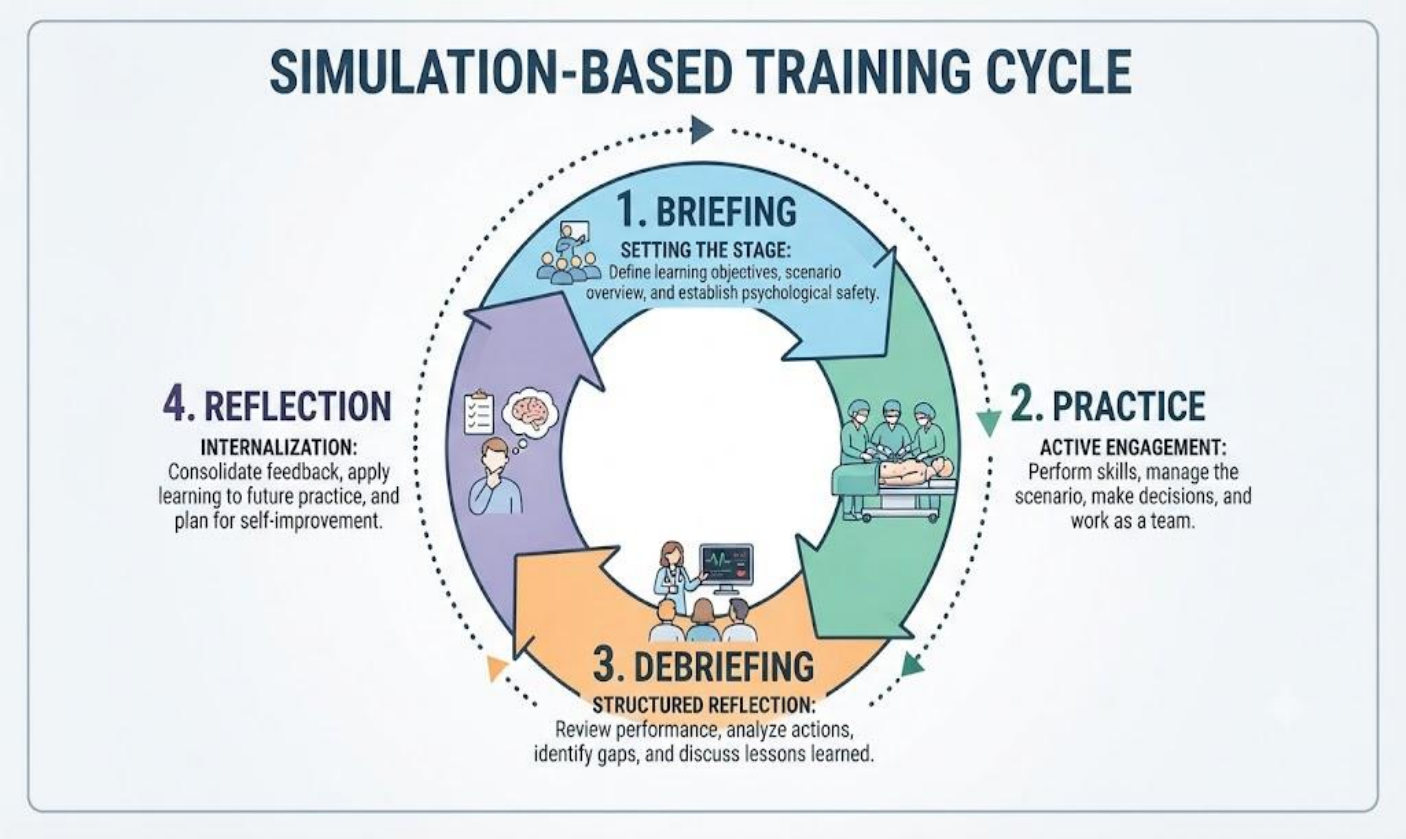

Figure 1.4: The simulation-based training cycle for developing gynaecological clinical skills.

Pilot questions 1.4

1. Describe the environmental considerations important in organising a gynaecological clinic. (Linked to SLO 1.5)

2. Describe the principles of effective time management within a gynaecological clinic. (Linked to SLO 1.5)
3. Explain the value of simulation-based training in developing gynaecological clinical skills. (Linked to SLO 1.6)
4. Describe the components of an effective simulation-based training programme. (Linked to SLO 1.6)
5. Explain why structured feedback is essential following simulation training. (Linked to SLO 1.6)

Series Summary

This Series has covered the structure and goals of the gynaecological consultation and the communication skills that support it, followed by professionalism, informed consent, and chaperoning. It went on to examine cultural sensitivity and special considerations for diverse patient groups, before concluding with the gynaecological clinic environment, workflow, and the role of simulation-based training in developing clinical skills.

You should now be able to demonstrate a structured approach to the gynaecological consultation, describe effective communication skills, describe the principles of professionalism, consent, and chaperoning, describe cultural sensitivity and special considerations, and describe the organisation of the clinic environment and the role of simulation-based training (Linked to SLOs 1.1 to 1.6).

Glossary of Terms

- **Active listening:** a communication technique involving appropriate eye contact, minimal interruption, and reflecting back what has been heard.
- **Chaperone:** an independent observer offered to a patient during an intimate examination, regardless of examiner gender.
- **Informed consent:** consent given by a patient with capacity, adequate information, and voluntariness, without coercion.
- **Professional boundaries:** the appropriate limits of the clinical relationship, particularly important given the intimate nature of gynaecological practice.
- **Rapport:** a relationship of mutual trust and understanding between clinician and patient.

laNETonline.com

- **Safeguarding:** measures taken to protect a vulnerable individual, such as a child or adult at risk, from harm.
- **Shared decision-making:** a collaborative process in which clinician and patient jointly reach a decision about care, respecting patient values and preferences.
- **Simulation-based training:** structured practice using manikins, simulated patients, or scenarios, allowing skill development without risk to real patients.
- **Standardised patient:** a person trained to consistently portray a patient case for the purposes of clinical training or assessment.
- **Structured debriefing:** a facilitated discussion following a simulation exercise, identifying learning points and areas for improvement.
- **Cultural sensitivity:** awareness of and respect for a patient's cultural and religious beliefs and their influence on healthcare preferences.
- **Open questioning:** a questioning technique using broad, non-leading questions to allow a patient to describe concerns in their own words.

Concept Check Questions [Series 1]

Objective questions

1. The goals of consultation include shared _____ that respects the woman's values and preferences.
2. Effective communication begins with _____ questioning, allowing the woman to describe her concerns in her own words.
3. Professional conduct includes appropriate dress, punctuality, and maintaining strict _____ of all information shared.
4. A chaperone should be offered to every woman undergoing a gynaecological examination, regardless of examiner _____.
5. Language barriers should be addressed using a professional _____ wherever possible, rather than relying on a family member.

Short-answer questions

6. Explain why building rapport and trust is a genuine clinical investment. (Linked to SLO 1.2)
7. Explain why consent can be withdrawn at any point during an examination. (Linked to SLO 1.3)

lanetonline.com

8. Describe the approach to consultation with an adolescent gynaecological patient. (Linked to SLO 1.4)
9. Describe the principles of effective time management within a gynaecological clinic. (Linked to SLO 1.5)
10. Explain why structured feedback is essential following simulation training. (Linked to SLO 1.6)

Long-answer questions

11. Describe the structure and goals of a gynaecological consultation, and the communication skills that support it. (Linked to SLO 1.1, SLO 1.2)
12. Describe the principles of professionalism, informed consent, and chaperoning in gynaecological practice. (Linked to SLO 1.3)
13. Describe cultural sensitivity and the special considerations required for adolescent patients and those with additional communication needs. (Linked to SLO 1.4)
14. Describe how to organise the gynaecological clinic environment and manage clinic workflow effectively. (Linked to SLO 1.5)
15. Describe the value and components of simulation-based training in developing gynaecological clinical skills. (Linked to SLO 1.6)

Answers to Concept Check Questions [Series 1]

Objective questions

1. Decision-making.
2. Open.
3. Confidentiality.
4. Gender.
5. Interpreter.

Short-answer questions

6. Trust encourages accurate disclosure of sensitive symptoms, genuine engagement with treatment, and return for necessary follow-up care.

lanetonline.com

7. Consent must be voluntary and can be withdrawn at any time, with the clinician stopping immediately if asked, respecting the woman's ongoing autonomy.
8. Balancing developing autonomy with parental involvement, offering time alone where appropriate, and being explicit about limits of confidentiality.
9. Structuring the encounter efficiently without rushing the woman, prioritising key elements when time is constrained, and being transparent about constraints.
10. It translates simulated practice into genuine improvement in real clinical performance, an essential component alongside repeated deliberate practice.

Long-answer questions

11. **Basic response:** The gynaecological consultation follows a structured sequence from introduction through history, examination, and planning, supported by open questioning and active listening.

Value-added response: Building genuine rapport and trust is a clinical investment that improves disclosure, engagement, and follow-up, not merely a courtesy.

12. **Basic response:** Professionalism includes appropriate conduct and boundaries, with informed consent requiring clear explanation and chaperoning offered to every patient.

Value-added response: Consent can be withdrawn at any point, and safeguarding dignity extends beyond chaperoning to privacy, draping, and explanation throughout examination.

13. **Basic response:** Cultural sensitivity requires individualised, respectful approaches, with adolescents needing a balance of autonomy and appropriate involvement of guardians.

Value-added response: Patients with additional communication needs require deliberate adaptation, including professional interpreters rather than family members for sensitive content.

Answers to Pilot Questions [Series 1]

Part 1.1

1. Introduction, history taking, examination where indicated, discussion of findings, and a clear follow-up plan.
2. Understanding the impact of symptoms on quality of life, shared decision-making, and ensuring the woman understands what happens next.

laNET | ONLINE LEARNING VIDEO PLATFORM FOR POST-SECONDARY & HIGHER INSTITUTION STUDENTS

3. Open questioning initially, active listening, and clear, jargon-free language the woman can understand and act upon.
4. A calm, unhurried manner and appropriate body language convey respect and care even before anything is said.
5. It improves disclosure of sensitive symptoms, engagement with treatment, and likelihood of returning for necessary follow-up.

Part 1.2

1. Appropriate dress and presentation, punctuality, confidentiality, and consistent courtesy and respect for every patient.
2. The intimate nature of gynaecological practice makes maintaining appropriate boundaries essential to trust and professional integrity.
3. Clear explanation of what is proposed, why, what it involves, and reasonable alternatives, given before the examination begins.
4. The woman retains autonomy throughout, and stopping immediately when asked respects that ongoing right to withdraw agreement.
5. A chaperone should be offered regardless of examiner gender, alongside privacy, appropriate draping, and explanation of each step.

Part 1.3

1. Beliefs can affect comfort discussing symptoms, examiner gender preference, and attitudes towards investigations or treatment.
2. Approaching each woman as an individual rather than assuming beliefs based on apparent ethnicity, religion, or region.
3. Balancing developing autonomy with appropriate guardian involvement, guided by assessed maturity and relevant local guidance.
4. Safeguarding concerns must be escalated regardless of the adolescent's preference for confidentiality, and this should be made explicit.
5. Professional interpreters, accessible written or pictorial information, and allowing additional consultation time.

lanetonline.com

Part 1.4

1. Adequate privacy, soundproofing, appropriately equipped rooms, and a comfortable waiting area.
2. Realistic appointment scheduling that allows more time for complex consultations, without treating every slot as interchangeable.
3. It allows safe, repeated practice of skills without risk of harm to a real patient, supporting learning from mistakes.
4. Structured feedback and repeated deliberate practice as core components, not a single disconnected exercise.
5. It translates simulated practice into genuine improvement in real clinical performance.

References and Attributions [Series 1]

Textual References

- Hoffman, B. L., Schorge, J. O., Halvorson, L. M. et al. (2020). Williams Gynecology (4th ed.). McGraw Hill.
- General Medical Council (2020). Intimate Examinations and Chaperones. GMC.
- Royal College of Obstetricians and Gynaecologists (2022). Gynaecological Examination: Guidance for Clinicians. RCOG Press.
- Ziv, A., Wolpe, P. R., Small, S. D. and Glick, S. (2003). Simulation-Based Medical Education: An Ethical Imperative. Academic Medicine, 78(8), 783 to 788.

Figures, Plates, Tables, and Boxes

- Figure 1.1: The structured stages of a gynaecological consultation. AI-generated using the prompt: "Create a professional medical flowchart titled Structure of the Gynaecological Consultation, showing sequential stages with communication skills annotated. Clean clinical educational diagram style."
- Box 1.2: Checklist for informed consent and chaperoning in gynaecological practice. AI-generated using the prompt: "Create a simple single-column reference box with an outside border titled Consent and Chaperoning Checklist, listing key elements for gynaecological practice. Clinical reference box style."
- Table 1.3: Special considerations and adaptations for diverse patient groups in gynaecological practice. AI-generated using the prompt: "Create a clean reference table titled Special

laNETonline.com

Considerations in Gynaecological Practice, listing patient groups and key adaptations for each. Simple clinical reference table style with outside border."

- Figure 1.4: The simulation-based training cycle for developing gynaecological clinical skills. AI-generated using the prompt: "Create a professional medical diagram titled Simulation-Based Training Cycle, showing briefing, practice, debriefing, and reflection in a cyclical process. Clean clinical educational diagram style."

lanetonline.com

Course code: OBG 507

Course title: Gynaecological Clinic and Simulation Training

Course credit load: 2 Units

Series 2: Symptoms, Signs and History Taking

- **Part 2.1: Menstrual and Bleeding Symptoms**
  - Sub Part 2.1.1: Menstrual symptoms and their terminology
  - Sub Part 2.1.2: Abnormal bleeding symptoms
  - Sub Part 2.1.3: Pain symptoms in gynaecology
- **Part 2.2: Discharge, Pelvic Mass, and Urinary Symptoms**
  - Sub Part 2.2.1: Vaginal discharge
  - Sub Part 2.2.2: Pelvic mass and swelling
  - Sub Part 2.2.3: Urinary and bowel symptoms in gynaecology
- **Part 2.3: Clinical Signs in Gynaecology**
  - Sub Part 2.3.1: General clinical signs relevant to gynaecology
  - Sub Part 2.3.2: Abdominal signs in gynaecology
  - Sub Part 2.3.3: Pelvic signs on examination
- **Part 2.4: History Taking in Gynaecology**
  - Sub Part 2.4.1: Structure of the gynaecological history
  - Sub Part 2.4.2: Menstrual, obstetric, and sexual history
  - Sub Part 2.4.3: Systematic history taking technique

lanetonline.com

Introduction

In the last Series, we explored how to approach the gynaecological patient with professionalism and sensitivity. We now turn to the substance of what every gynaecological consultation is built

around: the symptoms women describe, the signs a careful examiner can elicit, and the structured history taking technique that ties them together into a coherent clinical picture. Learning to recognise and precisely describe these symptoms and signs is the essential vocabulary of gynaecological practice, without which no diagnosis, however skilfully reasoned, can ever truly be reached.

The aim of this Series is to equip you with the knowledge to recognise and accurately describe the common symptoms and clinical signs of gynaecology, and the skill to take a structured, systematic gynaecological history.

We shall commence this Series by examining menstrual and abnormal bleeding symptoms, followed by pain as a gynaecological symptom. Next, we will consider vaginal discharge, pelvic mass, and urinary and bowel symptoms. Following that, our attention turns to the general, abdominal, and pelvic clinical signs identified on examination. Finally, we will conclude by examining the structure and technique of gynaecological history taking.

Series Learning Outcomes

Upon completing this Series, you should be able to:

- **SLO 2.1:** list and define common menstrual and abnormal bleeding symptoms,
- **SLO 2.2:** describe pain, including dyspareunia, as a gynaecological symptom,
- **SLO 2.3:** list and describe vaginal discharge, pelvic mass, and urinary or bowel symptoms in gynaecology,
- **SLO 2.4:** describe the general and abdominal clinical signs relevant to gynaecology,
- **SLO 2.5:** describe the pelvic signs identified on gynaecological examination,
- **SLO 2.6:** describe the structure of the gynaecological history, and
- **SLO 2.7:** demonstrate systematic history taking technique in gynaecology.

2.1 Menstrual and Bleeding Symptoms

2.1.1 Menstrual symptoms and their terminology

Precise terminology is essential when describing menstrual symptoms, as imprecise language can lead to genuine miscommunication between clinicians and, ultimately, diagnostic error: menorrhagia (now more commonly termed heavy menstrual bleeding) describes excessive menstrual blood loss, dysmenorrhoea describes painful periods, oligomenorrhoea describes

laNET | ONLINE LEARNING VIDEO PLATFORM FOR POST-SECONDARY & HIGHER INSTITUTION STUDENTS

lanetonline.com

infrequent periods with a cycle length greater than 35 days, and amenorrhoea describes the complete absence of periods, further subdivided into primary (never having menstruated) and secondary (cessation of previously established periods).

Establishing accurate menstrual terminology with the patient herself is an important, practical clinical skill, as women frequently use lay terms inconsistently or differently from clinical usage, meaning a clinician should always clarify precisely what a woman means by terms such as heavy, irregular, or painful periods, using specific, concrete questions about pad or tampon use, cycle length, and the functional impact of symptoms on daily activities, rather than assuming a shared, common understanding of these terms.

Fill in the blank: Excessive menstrual blood loss is now more commonly termed heavy menstrual bleeding, previously called _____. Amenorrhoea is subdivided into primary and _____, depending on whether periods have ever occurred.

2.1.2 Abnormal bleeding symptoms

Beyond disturbances of the menstrual cycle itself other patterns of abnormal bleeding carry specific clinical significance: intermenstrual bleeding (between otherwise regular periods), post-coital bleeding (after intercourse), and postmenopausal bleeding (occurring twelve months or more after the last menstrual period) each warrant a distinct, structured approach to further assessment, as each pattern is associated with a somewhat different range of underlying causes and, correspondingly, a different level of urgency for investigation.

Accurately characterising the specific pattern of bleeding reported by the patient, including its timing, quantity, and any clear relationship to intercourse or the menstrual cycle, is a genuinely essential first step in appropriately directing subsequent investigation, as failing to elicit this detail precisely can lead to inappropriate reassurance or, conversely, unnecessary anxiety and over-investigation of a symptom that has not actually been accurately characterised in the first place.

Fill in the blank: Postmenopausal bleeding is defined as bleeding occurring _____ months or more after the last menstrual period. Accurately characterising the timing, quantity, and relationship to intercourse of bleeding is essential in directing subsequent _____.

2.1.3 Pain symptoms in gynaecology

Pain is among the most common presenting symptoms in gynaecological practice, requiring systematic characterisation using a structured framework such as SOCRATES (site, onset, character, radiation, associated symptoms, timing, exacerbating and relieving factors, and severity), with specific attention to whether the pain is cyclical (suggesting a relationship to the menstrual cycle, as in dysmenorrhoea or mid-cycle ovulation pain) or acyclical (constant or unrelated to cycle timing).

Dyspareunia (pain during sexual intercourse) is a specific pain symptom requiring particularly sensitive enquiry, further characterised as superficial (at the entrance to the vagina, often related

la-NET | ONLINE LEARNING VIDEO PLATFORM FOR POST-SECONDARY & HIGHER INSTITUTION STUDENTS

to vulval or vaginal pathology or, in some cases, psychosexual factors) or deep (felt more internally, often related to pelvic pathology such as endometriosis or pelvic inflammatory disease), a distinction that meaningfully narrows the subsequent differential diagnosis.

Fill in the blank: The SOCRATES framework systematically characterises pain by site, onset, character, radiation, and _____. Dyspareunia is further characterised as superficial or _____, a distinction that narrows the differential diagnosis.

Term	Definition
Menorrhagia	Excessive menstrual blood loss (>80 mL per cycle) or prolonged bleeding (>7 days).
Dysmenorrhoea	Painful menstruation, typically cramping lower abdominal pain during menses.
Oligomenorrhoea	Infrequent menstrual periods, cycles >35 days apart.
Amenorrhoea	Absence of menstruation for ≥3 months (secondary) or failure to menstruate by age 15 (primary).
Intermenstrual Bleeding	Vaginal bleeding occurring between regular menstrual periods.
Post-Coital Bleeding	Vaginal bleeding occurring after sexual intercourse.
Postmenopausal Bleeding	Vaginal bleeding occurring >12 months after the last menstrual period.

Table 2.1: Glossary of menstrual and bleeding symptom terminology.

Pilot questions 2.1

- Define menorrhagia, dysmenorrhoea, oligomenorrhoea, and amenorrhoea. (Linked to SLO 2.1)
- Explain why clarifying menstrual terminology with the patient herself is important. (Linked to SLO 2.1)
- Distinguish intermenstrual, post-coital, and postmenopausal bleeding. (Linked to SLO 2.1)
- Describe the SOCRATES framework as applied to gynaecological pain. (Linked to SLO 2.2)
- Distinguish superficial from deep dyspareunia and its clinical significance. (Linked to SLO 2.2)

la-NET | ONLINE LEARNING VIDEO PLATFORM FOR POST-SECONDARY & HIGHER INSTITUTION STUDENTS

2.2 Discharge, Pelvic Mass, and Urinary Symptoms

2.2.1 Vaginal discharge

Vaginal discharge is a common presenting symptom with a wide differential, from entirely physiological, cyclical discharge (clear or white, odourless, varying with the menstrual cycle) to pathological discharge from infection (bacterial vaginosis, candidiasis, or a sexually transmitted infection) or, less commonly, malignancy, with the colour, consistency, odour, and any associated symptoms such as itching or soreness each providing important diagnostic clues.

Specific characteristics of discharge can suggest a particular underlying cause, though none should be relied upon in isolation for diagnosis: a thick, white, curd-like discharge with itching suggests candidiasis, a thin, grey, fishy-smelling discharge suggests bacterial vaginosis, and a frothy, yellow-green discharge suggests trichomoniasis, though definitive diagnosis in each case requires appropriate examination and microbiological testing rather than reliance on the history and description alone.

Fill in the blank: A thick, white, curd-like discharge with itching classically suggests _____. Definitive diagnosis of the cause of discharge requires appropriate examination and _____ testing rather than history alone.

2.2.2 Pelvic mass and swelling

A pelvic mass or swelling may be noticed by the woman herself as abdominal distension or a palpable lump, or, frequently, identified incidentally during clinical examination or imaging performed for an unrelated reason, with a broad differential diagnosis spanning gynaecological (fibroid, ovarian cyst or tumour, pregnancy), gastrointestinal, and urological origin, meaning a genuinely systematic approach to characterising and localising the mass is essential.

Key characteristics to elicit and assess when a pelvic mass or swelling is present include its size, rate of growth, any associated pain, and, when combined with abdominal palpation on examination, whether the examiner can palpate below the mass, a finding that helps distinguish a mass arising from the pelvis, which cannot be got below, from one of primarily abdominal origin.

Fill in the blank: The differential diagnosis of a pelvic mass spans gynaecological, gastrointestinal, and _____ origin. The inability to palpate below a mass on abdominal examination helps identify a mass arising from the _____.

2.2.3 Urinary and bowel symptoms in gynaecology

Urinary symptoms are frequently relevant in gynaecological presentations given the close anatomical relationship between the pelvic organs and the bladder and urethra, including urinary frequency, urgency, incontinence (stress, urge, or mixed), and dysuria, each requiring specific characterisation, as the pattern of symptoms substantially narrows the likely underlying cause and appropriate subsequent investigation.

lanetonline.com

Bowel symptoms including altered bowel habit, tenesmus, and pain on defecation can similarly reflect gynaecological pathology, particularly endometriosis affecting the bowel or a pelvic mass exerting pressure on adjacent bowel, making enquiry about both urinary and bowel symptoms a routine, standard component of a comprehensive gynaecological history rather than an optional addition considered only when volunteered spontaneously by the patient.

Fill in the blank: Urinary incontinence is classified as stress, urge, or _____. Enquiry about bowel symptoms should be a routine, standard component of a comprehensive gynaecological _____.

Feature / Symptom	Key Details
Candidiasis	Thick, white, "cottage cheese" discharge; intense itching and vulval soreness.
Bacterial Vaginosis	Thin, grey-white discharge; fishy odor, especially after intercourse.
Trichomoniasis	Frothy, yellow-green discharge; vulval irritation; "strawberry cervix" on exam.
Urinary Symptoms	Dysuria, frequency, urgency, haematuria.
Bowel Symptoms	Constipation, diarrhoea, rectal pressure, pain on defecation.

Box 2.2: Characteristic features of vaginal discharge and relevant urinary and bowel symptoms.

Pilot questions 2.2

1. Distinguish physiological from pathological vaginal discharge. (Linked to SLO 2.3)
2. Describe the characteristic features of discharge in candidiasis, bacterial vaginosis, and trichomoniasis. (Linked to SLO 2.3)
3. Describe the key characteristics to assess in a woman presenting with a pelvic mass. (Linked to SLO 2.3)
4. Describe the urinary symptoms relevant to gynaecological assessment. (Linked to SLO 2.3)
5. Explain why bowel symptoms should be routinely enquired about in a gynaecological history. (Linked to SLO 2.3)

lanetonline.com

2.3 Clinical Signs in Gynaecology

2.3.1 General clinical signs relevant to gynaecology

General examination in gynaecological practice can reveal signs relevant to the presenting complaint even before any pelvic assessment begins: pallor may suggest anaemia from heavy menstrual bleeding, hirsutism or acne may suggest an underlying androgen excess disorder such as polycystic ovary syndrome, and abnormal body mass index, whether elevated or reduced, is relevant to menstrual disturbance, fertility, and the interpretation of many gynaecological presentations.

Lymphadenopathy (particularly inguinal lymph nodes, given their drainage relationship with the vulva and lower vagina) and signs of systemic illness such as fever or tachycardia are further general signs of specific relevance in gynaecological assessment, each potentially providing an important clue to the underlying diagnosis that would be entirely missed if general examination were omitted in favour of proceeding directly to a purely pelvic-focused assessment.

Fill in the blank: Hirsutism or acne on general examination may suggest an underlying _____ excess disorder such as polycystic ovary syndrome. Inguinal lymphadenopathy is relevant given its drainage relationship with the _____ and lower vagina.

2.3.2 Abdominal signs in gynaecology

Abdominal examination in gynaecological assessment follows the standard sequence of inspection (for scars, distension, or visible masses), palpation (for tenderness, masses, and organomegaly), percussion (distinguishing a solid mass from ascites or bowel distension), and auscultation, with specific attention to signs of peritonism, including guarding, rigidity, and rebound tenderness, which suggest significant intra-abdominal pathology requiring urgent further assessment.

Rovsing's sign (pain in the right iliac fossa elicited by palpation of the left iliac fossa, classically associated with appendicitis) and other specific abdominal signs are of relevance in the gynaecological patient given the substantial diagnostic overlap between acute gynaecological and gastrointestinal presentations, reinforcing why abdominal examination should never be omitted or rushed in a woman presenting with acute pelvic or lower abdominal pain.

Fill in the blank: Peritonism on abdominal examination is suggested by guarding, rigidity, and _____ tenderness. Rovsing's sign is pain in the right iliac fossa elicited by palpation of the _____ iliac fossa.

2.3.3 Pelvic signs on examination

Pelvic examination can reveal a range of specific signs, including cervical excitation tenderness (pain on movement of the cervix during bimanual examination, suggestive of pelvic inflammatory disease or ectopic pregnancy), adnexal tenderness or a palpable adnexal mass, and abnormalities of the cervix itself (such as visible lesion, contact bleeding, or an open os), each

lanet.online.com

carrying specific diagnostic significance that should be systematically sought and documented during examination.

Uterine size, shape, position, mobility, and tenderness assessed on bimanual examination provide further important diagnostic information, with a bulky, tender uterus suggesting adenomyosis or early pregnancy, a fixed, immobile uterus suggesting adhesions from endometriosis or prior infection, and an irregularly enlarged uterus suggesting fibroids, illustrating how careful, systematic pelvic examination genuinely narrows the differential diagnosis well beyond what history alone can achieve.

Fill in the blank: Cervical excitation tenderness on bimanual examination is suggestive of pelvic inflammatory disease or _____ pregnancy. A fixed, immobile uterus on examination suggests _____ from endometriosis or prior infection.

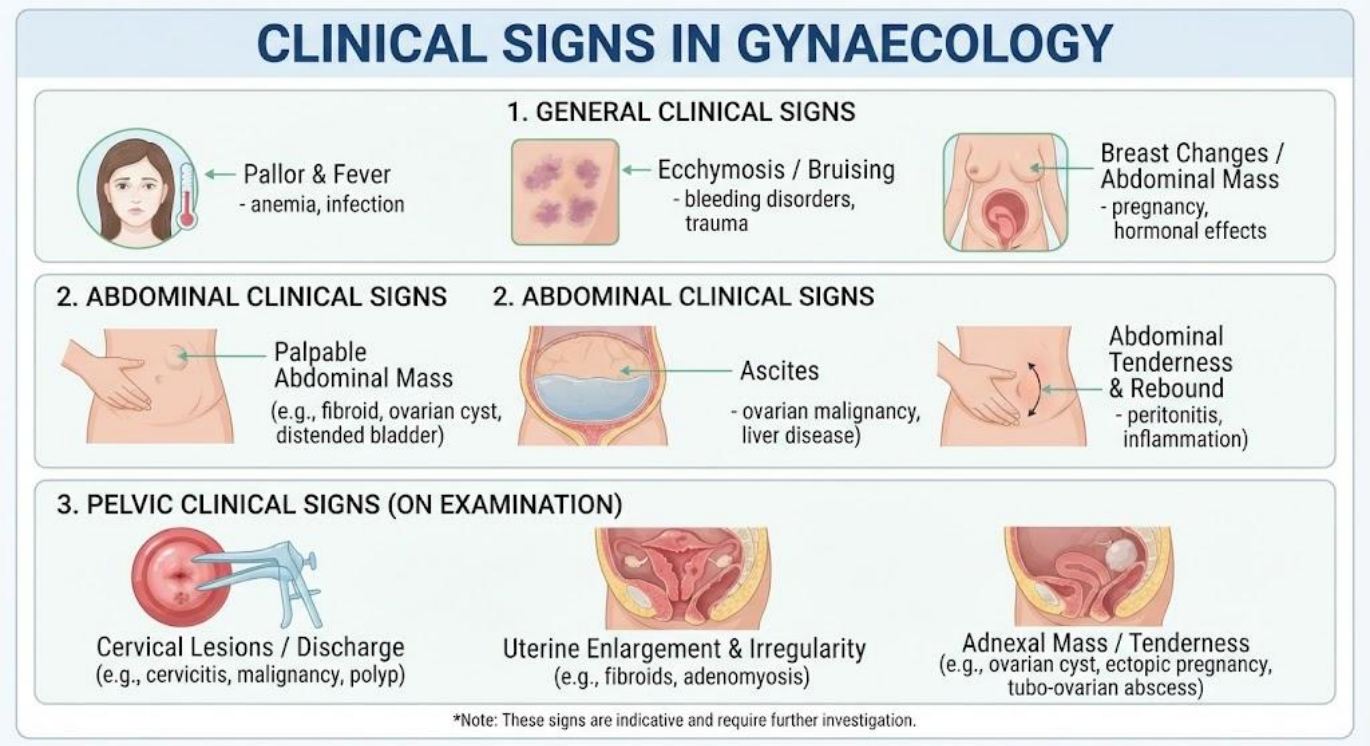

Figure 2.3: General, abdominal, and pelvic clinical signs in gynaecology.

Pilot questions 2.3

1. Describe the general clinical signs relevant to gynaecological assessment. (Linked to SLO 2.4)
2. Describe the standard sequence of abdominal examination in gynaecology. (Linked to SLO 2.4)
3. Describe the signs of peritonism and their clinical significance. (Linked to SLO 2.4)

4. Describe cervical excitation tenderness and its clinical significance. (Linked to SLO 2.5)
5. Describe the findings assessed on bimanual examination of the uterus. (Linked to SLO 2.5)

2.4 History Taking in Gynaecology

2.4.1 Structure of the gynaecological history

A comprehensive gynaecological history follows a structured, chronological sequence, beginning with biodata and the presenting complaint (recorded as far as possible in the patient's own words), followed by history of presenting complaint, menstrual history, obstetric history, sexual history, past medical and surgical history, drug history and allergies, and family and social history, with each section building systematically on the information gathered before it.

Following a consistent, structured template for every gynaecological history, rather than an ad hoc or inconsistent approach that varies from patient to patient, reduces the risk of omitting clinically important information, supports accurate and complete documentation, and allows more efficient, focused history taking over time as the structure becomes genuinely familiar and internalised through consistent, repeated practice.

Fill in the blank: The gynaecological history begins with biodata and the presenting complaint, recorded as far as possible in the patient's own _____. Following a consistent, structured _____ for every history reduces the risk of omitting important information.

2.4.2 Menstrual, obstetric, and sexual history

The menstrual history records age at menarche, cycle length and regularity, duration and quantity of bleeding, and the date of the last menstrual period, while the obstetric history uses the gravida and para system to record the total number of pregnancies and the number reaching viable gestation, with details of each pregnancy's outcome and any complications recorded systematically.

The sexual history should be taken sensitively and without judgement, covering current sexual activity, contraceptive use, and, where clinically relevant, risk factors for sexually transmitted infection, with the specific depth and detail of questioning tailored to the presenting complaint and the woman's own comfort, rather than applying an identical, rigid script to every consultation regardless of its actual clinical relevance to the presenting concern.

Fill in the blank: The obstetric history uses the gravida and _____ system to record pregnancy outcomes. The sexual history should be taken sensitively and without _____, tailored to the presenting complaint.

la-net online.com

2.4.3 Systematic history taking technique

Systematic history taking technique combines open questioning at the outset of each section, allowing the woman to elaborate in her own words, with more specific, closed questions used to clarify particular details once the broad picture has been established, avoiding leading questions that might inadvertently suggest a particular answer or bias the information obtained from the patient.

Throughout history taking the clinician should actively summarise and reflect back key information periodically, both to confirm accurate understanding and to demonstrate active listening to the patient, while remaining alert to cues, verbal or non-verbal, that suggest an area of particular sensitivity or concern warranting a more gentle, unhurried approach rather than continuing briskly through a standard, predetermined question sequence regardless of the patient's evident response.

Fill in the blank: Systematic history taking uses open questioning initially, followed by more specific, _____ questions to clarify detail. The clinician should periodically summarise and _____ back key information to confirm accurate understanding.

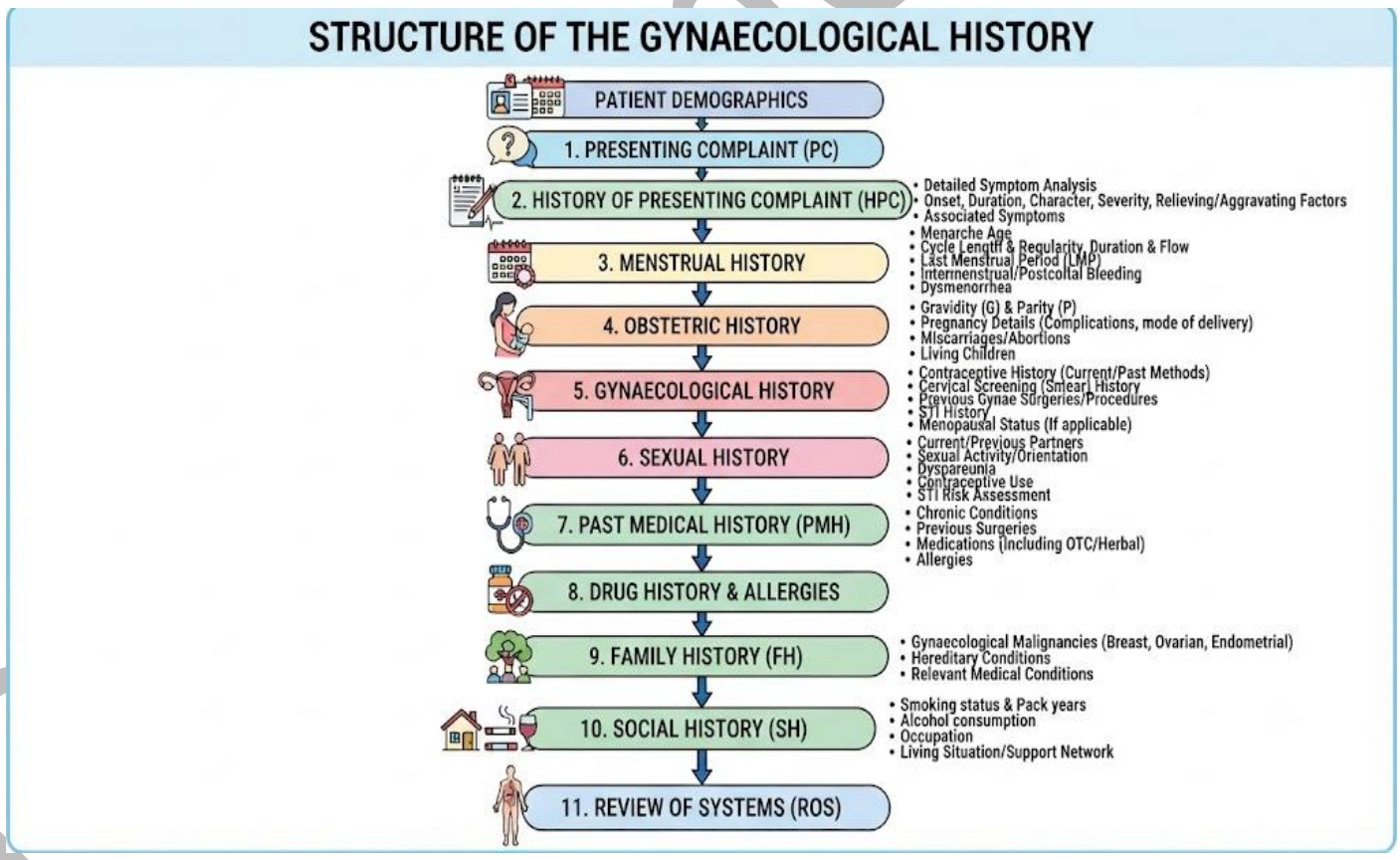

Figure 2.4: Sequential structure of the comprehensive gynaecological history.

Pilot questions 2.4

1. Describe the sequential structure of a comprehensive gynaecological history. (Linked to SLO 2.6)
2. Explain the value of following a consistent, structured template for every gynaecological history. (Linked to SLO 2.6)
3. Describe the components of the menstrual and obstetric history. (Linked to SLO 2.7)
4. Describe the principles of taking a sensitive sexual history. (Linked to SLO 2.7)
5. Describe the systematic technique used to combine open and closed questioning during history taking. (Linked to SLO 2.7)

Series Summary

This Series has covered menstrual and abnormal bleeding symptoms, followed by pain as a gynaecological symptom, and vaginal discharge, pelvic mass, and urinary and bowel symptoms. It went on to examine the general, abdominal, and pelvic clinical signs identified on examination, before concluding with the structure and systematic technique of gynaecological history taking.

You should now be able to list and define the common menstrual and bleeding symptoms, describe pain and dyspareunia, describe discharge, mass, and urinary or bowel symptoms, describe general, abdominal, and pelvic clinical signs, and describe the structure and technique of gynaecological history taking (Linked to SLOs 2.1 to 2.7).

Glossary of Terms

1. **Amenorrhoea:** the complete absence of menstrual periods, classified as primary or secondary.
2. **Cervical excitation tenderness:** pain elicited on movement of the cervix during bimanual examination.
3. **Dyspareunia:** pain during sexual intercourse, classified as superficial or deep.
4. **Dysmenorrhoea:** painful menstrual periods.

lanetonline.com

5. **Heavy menstrual bleeding:** excessive menstrual blood loss, previously termed menorrhagia.
6. **Oligomenorrhoea:** infrequent menstrual periods, with a cycle length greater than 35 days.
7. **Postmenopausal bleeding:** vaginal bleeding occurring twelve months or more after the last menstrual period.
8. **Rovsing's sign:** pain in the right iliac fossa elicited by palpation of the left iliac fossa, classically associated with appendicitis.
9. **SOCRATES:** a mnemonic for systematically characterising pain: site, onset, character, radiation, associated symptoms, timing, exacerbating and relieving factors, and severity.
10. **Tenesmus:** a sensation of incomplete bowel emptying, a bowel symptom relevant to gynaecological assessment.
11. **Peritonism:** clinical signs, including guarding and rigidity, suggesting irritation of the peritoneum.
12. **Gravida and para:** a system recording the total number of pregnancies (gravida) and the number reaching viable gestation (para).

Concept Check Questions [Series 2]

Objective questions

- Amenorrhoea is subdivided into primary and _____, depending on whether periods have ever occurred.
- Postmenopausal bleeding is defined as bleeding occurring _____ months or more after the last menstrual period.
- A thick, white, curd-like discharge with itching classically suggests _____.
- Rovsing's sign is pain in the right iliac fossa elicited by palpation of the _____ iliac fossa.
- Cervical excitation tenderness is suggestive of pelvic inflammatory disease or _____ pregnancy.

Short-answer questions

laNETonline.com

1. Distinguish superficial from deep dyspareunia and its clinical significance. (Linked to SLO 2.2)
2. Describe the key characteristics to assess in a woman presenting with a pelvic mass. (Linked to SLO 2.3)
3. Describe the signs of peritonism and their clinical significance. (Linked to SLO 2.4)
4. Describe the findings assessed on bimanual examination of the uterus. (Linked to SLO 2.5)
5. Explain the value of following a consistent, structured template for every gynaecological history. (Linked to SLO 2.6)

Long-answer questions

6. Describe the common menstrual and bleeding symptoms in gynaecology, including their precise terminology. (Linked to SLO 2.1)
7. Describe the presentation of vaginal discharge, pelvic mass, and urinary and bowel symptoms in gynaecology. (Linked to SLO 2.3)
8. Describe the general, abdominal, and pelvic clinical signs relevant to gynaecological assessment. (Linked to SLO 2.4, SLO 2.5)
9. Describe the structure of a comprehensive gynaecological history. (Linked to SLO 2.6)
10. Describe the systematic technique used in gynaecological history taking. (Linked to SLO 2.7)

Answers to Concept Check Questions [Series 2]

Objective questions

11. Secondary.
12. Twelve.
13. Candidiasis.
14. Left.
15. Ectopic.

lanetonline.com

Short-answer questions

16. Superficial dyspareunia relates to vulval or vaginal pathology; deep dyspareunia relates more to pelvic pathology such as endometriosis.
17. Size, rate of growth, associated pain, and whether the examiner can palpate below the mass on abdominal examination.
18. Guarding, rigidity, and rebound tenderness suggest significant intra-abdominal pathology requiring urgent further assessment.
19. Size, shape, position, mobility, and tenderness, each providing diagnostic clues to the underlying pathology.
20. It reduces the risk of omitting important information, supports accurate documentation, and allows more efficient history taking over time.

Long-answer questions

21. **Basic response:** Menstrual symptoms include heavy bleeding, dysmenorrhoea, oligomenorrhoea, and amenorrhoea, with bleeding also classified by timing as intermenstrual, post-coital, or postmenopausal.

Value-added response: Precise terminology and clarification with the patient herself are essential, as lay and clinical usage of terms such as heavy or irregular can differ substantially.

22. **Basic response:** Discharge, pelvic mass, and urinary or bowel symptoms each have characteristic features that narrow the differential diagnosis when carefully elicited.

Value-added response: The inability to palpate below a pelvic mass and the specific character of discharge both provide clinically valuable diagnostic clues.

23. **Basic response:** General, abdominal, and pelvic signs together provide a comprehensive picture, from pallor and lymphadenopathy to cervical excitation and uterine findings.

Value-added response: Signs of peritonism and Rovsing's sign are particularly important given the diagnostic overlap between gynaecological and gastrointestinal presentations.

lanetonline.com

Answers to Pilot Questions [Series 2]

Part 2.1

1. Menorrhagia is heavy bleeding, dysmenorrhoea is painful periods, oligomenorrhoea is infrequent periods, and amenorrhoea is absence of periods.
2. Lay and clinical usage of terms such as heavy or irregular can differ, so clarification avoids miscommunication and diagnostic error.
3. Intermenstrual bleeding occurs between periods, post-coital bleeding follows intercourse, and postmenopausal bleeding occurs after 12 months of amenorrhoea.
4. Site, onset, character, radiation, associated symptoms, timing, exacerbating and relieving factors, and severity.
5. Superficial dyspareunia suggests vulval or vaginal pathology; deep dyspareunia suggests pelvic pathology such as endometriosis.

Part 2.2

6. Physiological discharge is clear or white and odourless; pathological discharge reflects infection or, rarely, malignancy.
7. Candidiasis causes thick, white, curd-like discharge; bacterial vaginosis causes thin, grey, fishy discharge; trichomoniasis causes frothy, yellow-green discharge.
8. Size, growth rate, associated pain, and whether the mass can be palpated from below on abdominal examination.
9. Frequency, urgency, incontinence (stress, urge, or mixed), and dysuria.
10. Bowel symptoms can reflect gynaecological pathology such as endometriosis or a pressing pelvic mass, so routine enquiry is important.

Part 2.3

11. Pallor, hirsutism or acne, abnormal body mass index, lymphadenopathy, and signs of systemic illness such as fever.
12. Inspection, palpation, percussion, and auscultation, in that standard sequence.

lanetonline.com

13. Guarding, rigidity, and rebound tenderness suggest significant intra-abdominal pathology requiring urgent assessment.
14. Pain on movement of the cervix, suggestive of pelvic inflammatory disease or ectopic pregnancy.
15. Uterine size, shape, position, mobility, and tenderness, each providing important diagnostic clues.

Part 2.4

1. Biodata, presenting complaint, history of presenting complaint, menstrual, obstetric, sexual, past medical, drug, and social history.
2. A consistent structure reduces omissions, supports accurate documentation, and becomes more efficient with practice.
3. Menstrual history covers menarche, cycle pattern, and bleeding; obstetric history uses gravida and para to record pregnancy outcomes.
4. Sensitively, without judgement, tailoring depth and detail to the presenting complaint and the woman's comfort.
5. Open questioning initially, followed by specific closed questions to clarify detail, avoiding leading questions.

References and Attributions [Series 2]

Textual References

1. Hoffman, B. L., Schorge, J. O., Halvorson, L. M. et al. (2020). Williams Gynecology (4th ed.). McGraw Hill.
2. Talley, N. J. and O'Connor, S. (2017). Clinical Examination: A Systematic Guide to Physical Diagnosis (8th ed.). Elsevier.
3. Berek, J. S. and Berek, D. L. (2019). Berek and Novak's Gynecology (16th ed.). Wolters Kluwer.
4. Royal College of Obstetricians and Gynaecologists (2018). Heavy Menstrual Bleeding: Assessment and Management. NICE Guideline NG88.

lanetonline.com

Figures, Plates, Tables, and Boxes

1. Table 2.1: Glossary of menstrual and bleeding symptom terminology. AI-generated using the prompt: "Create a clean reference table titled Menstrual and Bleeding Symptom Terminology, defining key terms used in gynaecological practice. Simple clinical reference table style with outside border."
2. Box 2.2: Characteristic features of vaginal discharge and relevant urinary and bowel symptoms. AI-generated using the prompt: "Create a simple single-column reference box with an outside border titled Discharge, Urinary, and Bowel Symptoms, listing characteristic discharge features and relevant symptoms. Clinical reference box style."
3. Figure 2.3: General, abdominal, and pelvic clinical signs in gynaecology. AI-generated using the prompt: "Create a professional medical diagram titled Clinical Signs in Gynaecology, showing general, abdominal, and pelvic signs in three panels. Clean clinical educational diagram style."
4. Figure 2.4: Sequential structure of the comprehensive gynaecological history. AI-generated using the prompt: "Create a professional medical flowchart titled Structure of the Gynaecological History, showing the sequential sections of a comprehensive history. Clean clinical educational diagram style."

lanetonline.com

Course code: OBG 507

Course title: Gynaecological Clinic and Simulation Training

Course credit load: 2 Units

Series 3: General and Pelvic Examination

- **Part 3.1: Preparation, Inspection, and Vital Signs**
  - Sub Part 3.1.1: Preparing for gynaecological examination
  - Sub Part 3.1.2: General inspection and vital signs
  - Sub Part 3.1.3: Examination of the breast
- **Part 3.2: Systemic Examination Relevant to Gynaecology**
  - Sub Part 3.2.1: Thyroid and endocrine examination relevant to gynaecology
  - Sub Part 3.2.2: Abdominal examination technique
  - Sub Part 3.2.3: Examination for lymphadenopathy and signs of systemic disease
- **Part 3.3: Pelvic Examination: Positioning, Inspection, and Speculum Technique**
  - Sub Part 3.3.1: Positioning and preparation for pelvic examination
  - Sub Part 3.3.2: Inspection of the external genitalia
  - Sub Part 3.3.3: Speculum examination technique
- **Part 3.4: Bimanual and Special Pelvic Examination Techniques**
  - Sub Part 3.4.1: Bimanual pelvic examination technique
  - Sub Part 3.4.2: Rectal and rectovaginal examination
  - Sub Part 3.4.3: Special examination techniques

lanetonline.com

Introduction

In the last Series, we explored the symptoms and signs of gynaecological presentation and the structure of history taking. A history, however carefully taken, is only ever half of the clinical picture. This Series turns to the other half: the practical skill of examination itself, from the general assessment that begins the moment a woman enters the room, through to the pelvic examination that so often lies at the heart of a definitive gynaecological diagnosis. Developing

genuine competence and confidence in these techniques, practised first through simulation, is what this course exists to help you achieve.

The aim of this Series is to equip you with the knowledge and practical skill to perform a competent general physical examination and a systematic, respectful pelvic examination in gynaecological practice.

We shall commence this Series by examining preparation, general inspection, and vital sign assessment, together with breast examination. Next, we will consider systemic examination relevant to gynaecology, including thyroid, abdominal, and lymph node assessment. Following that, our attention turns to pelvic examination, beginning with positioning, inspection, and speculum technique. Finally, we will conclude by examining bimanual pelvic examination and special techniques, including rectal, rectovaginal, and examination under anaesthesia.

Series Learning Outcomes

Upon completing this Series, you should be able to:

- **SLO 3.1:** describe preparation for gynaecological examination and demonstrate general inspection and vital sign assessment,
- **SLO 3.2:** demonstrate breast examination relevant to gynaecological screening,
- **SLO 3.3:** demonstrate the systemic examination relevant to gynaecology, including thyroid, abdominal, and lymph node assessment,
- **SLO 3.4:** describe positioning and preparation for pelvic examination,
- **SLO 3.5:** demonstrate inspection and speculum examination technique,
- **SLO 3.6:** demonstrate bimanual pelvic examination technique, and
- **SLO 3.7:** describe rectal, rectovaginal, and special examination techniques.

3.1 Preparation, Inspection, and Vital Signs

3.1.1 Preparing for gynaecological examination

Thorough preparation before any gynaecological examination includes obtaining informed consent, explaining the purpose and process of the examination in language the woman can genuinely understand, offering a chaperone regardless of examiner gender, and ensuring the examination room provides adequate privacy, appropriate lighting, and all necessary equipment is readily available and in good working order before the woman is asked to undress.

laNET | ONLINE LEARNING VIDEO PLATFORM FOR POST-SECONDARY & HIGHER INSTITUTION STUDENTS

The clinician's own preparation is equally important, including hand hygiene immediately before the examination begins, appropriate use of personal protective equipment such as gloves, and a clear mental structure for the sequence of examination to be performed, ensuring the assessment proceeds efficiently, systematically, and without unnecessary repetition or omission once it is actually underway.

Fill in the blank: Thorough preparation includes obtaining informed consent and offering a chaperone regardless of examiner _____. The clinician's own preparation includes hand _____ immediately before the examination begins.

3.1.2 General inspection and vital signs

General inspection begins the moment the woman enters the consultation room, noting her general demeanour, apparent distress or discomfort, gait, and any obvious physical findings such as pallor, jaundice, or visible swelling, observations that, though easily overlooked in the rush to proceed to more formal assessment, frequently provide valuable diagnostic information available nowhere else in the examination.

Vital sign measurement (pulse rate, blood pressure, temperature, and, where clinically indicated, respiratory rate and oxygen saturation) should be performed using correctly sized and calibrated equipment and appropriate technique, with results interpreted in the context of the woman's presenting complaint, as abnormal vital signs in an otherwise apparently well woman may be the first objective clue to significant underlying pathology.

Fill in the blank: General inspection begins the moment the woman enters the _____, noting demeanour, distress, and obvious physical findings. Vital sign measurement should use correctly sized and calibrated _____ and appropriate technique.

3.1.3 Examination of the breast

Breast examination is a relevant component of general examination in gynaecological practice given the shared hormonal influences on the breast and reproductive organs, and any woman presenting with a breast-related concern should undergo systematic inspection (for asymmetry, skin changes, or nipple abnormality) and palpation (assessing for a discrete lump, tenderness, or nipple discharge) following the principles of triple assessment established in general gynaecological practice.

Any breast finding that raises concern, particularly a discrete, hard, irregular, or fixed lump, skin dimpling, or nipple retraction or bloody discharge, should prompt urgent referral for further imaging and, where indicated, biopsy, following the same red flag principles that apply throughout gynaecological and general clinical practice, rather than being managed with reassurance alone pending routine review.

Fill in the blank: Breast examination in gynaecological practice reflects the shared hormonal _____ on the breast and reproductive organs. Concerning breast findings should prompt urgent referral for further imaging following _____ flag principles.

la-NET | ONLINE LEARNING VIDEO PLATFORM FOR POST-SECONDARY & HIGHER INSTITUTION STUDENTS

Step	Key Details
Obtain Consent	Explain the procedure, risks, and purpose; ensure voluntary agreement.
Offer Chaperone	Provide a trained chaperone for patient comfort and safeguarding.
Ensure Privacy	Use a private room, appropriate draping, and maintain dignity.
Check Equipment	Confirm availability and functionality of speculum, light source, swabs, gloves, and lubricants.
Hand Hygiene	Wash hands thoroughly and use appropriate protective equipment.
Patient Positioning	Position comfortably, explain each step, and adjust for patient needs.
Documentation	Record consent, findings, and any complications clearly in notes.

Box 3.1: Essential preparation steps before gynaecological examination.

Pilot questions 3.1

- Describe the essential preparation steps before a gynaecological examination. (Linked to SLO 3.1)
- Describe the components of general inspection at the start of an examination. (Linked to SLO 3.1)
- Describe the vital signs that should be measured and their clinical relevance. (Linked to SLO 3.1)
- Describe the technique of breast inspection and palpation. (Linked to SLO 3.2)
- List the breast findings that should prompt urgent referral. (Linked to SLO 3.2)

3.2 Systemic Examination Relevant to Gynaecology

3.2.1 Thyroid and endocrine examination relevant to gynaecology

Thyroid examination is relevant in gynaecological assessment given the recognised association between thyroid dysfunction and menstrual irregularity, subfertility, and pregnancy complications, performed by inspection (for visible goitre or asymmetry), palpation (assessing size, consistency, and any nodularity, typically from behind the seated patient), and, where indicated, auscultation for a bruit suggestive of hyperthyroidism.

Other endocrine signs relevant to gynaecological presentation include hirsutism, acne, and acanthosis nigricans (a velvety, hyperpigmented skin change often seen at the neck or axillae, associated with insulin resistance), all of which may suggest an underlying androgen excess or

la-NET | ONLINE LEARNING VIDEO PLATFORM FOR POST-SECONDARY & HIGHER INSTITUTION STUDENTS

lanetonline.com

metabolic disorder such as polycystic ovary syndrome, warranting specific, deliberate examination for these signs in any woman presenting with menstrual irregularity or subfertility.

Fill in the blank: Thyroid palpation is typically performed from _____ the seated patient. Acanthosis nigricans is a velvety, hyperpigmented skin change associated with insulin _____.

3.2.2 Abdominal examination technique

Abdominal examination technique follows the standard sequence of inspection, palpation, percussion, and auscultation, with palpation beginning gently and superficially, away from any area of reported pain, before proceeding to deeper palpation, systematically assessing all four quadrants for tenderness, masses, and organomegaly, with any area of tenderness or an identified mass further characterised for its size, consistency, mobility, and relationship to surrounding structures.

Specific technique points relevant to gynaecological abdominal examination include assessing whether a pelvic mass can be palpated 'from below', a key distinguishing feature from an intra-abdominal mass of non-pelvic origin, and eliciting specific signs such as rebound tenderness and guarding, which, when present, suggest peritoneal irritation and warrant urgent further assessment rather than routine, non-urgent follow-up.

Fill in the blank: Abdominal palpation should begin gently and superficially, away from any area of reported _____. A pelvic mass characteristically cannot be palpated from _____ on abdominal examination.

3.2.3 Examination for lymphadenopathy and signs of systemic disease

Examination for lymphadenopathy relevant to gynaecological practice focuses particularly on the inguinal region, given its lymphatic drainage relationship with the vulva and lower vagina, assessed by careful palpation for size, consistency, tenderness, and mobility of any palpable nodes, with hard, fixed, non-tender lymphadenopathy raising particular concern for malignant infiltration warranting further urgent investigation.

Signs of systemic disease that may be relevant to a gynaecological presentation include jaundice (suggesting liver involvement, relevant in some malignancies or severe pre-eclampsia), peripheral oedema (relevant to venous or lymphatic obstruction from a pelvic mass, or to pre-eclampsia in the pregnant patient), and cachexia or unintentional weight loss (a concerning finding warranting active exclusion of underlying malignancy), all of which should be actively sought as part of a comprehensive general examination.

Fill in the blank: Inguinal lymphadenopathy is particularly relevant given its drainage relationship with the vulva and lower _____. Hard, fixed, non-tender lymphadenopathy raises particular concern for malignant _____.

laNETonline.com

Finding	Clinical Significance
Pallor	Suggests anaemia, often due to chronic heavy menstrual bleeding or malignancy.
Jaundice	May indicate liver disease, haemolysis, or metastatic spread affecting hepatic function.
Lymphadenopathy	Could suggest pelvic or systemic infection, lymphoma, or metastatic gynaecological cancer.
Thyroid Enlargement	Associated with menstrual irregularities, infertility, or amenorrhoea due to thyroid dysfunction.
Breast Changes	Galactorrhoea may indicate hyperprolactinaemia; masses may suggest breast malignancy.
Ascites	May point to advanced ovarian cancer, liver disease, or peritoneal tuberculosis.
Lower Limb Oedema	Can be due to pelvic mass compressing venous return, cardiac disease, or renal dysfunction.

Table 3.2: Systemic examination findings relevant to gynaecological assessment.

Pilot questions 3.2

1. Describe the technique of thyroid examination and its relevance to gynaecology. (Linked to SLO 3.3)
2. Describe the endocrine signs relevant to a woman presenting with menstrual irregularity. (Linked to SLO 3.3)
3. Describe the standard sequence and technique of abdominal examination. (Linked to SLO 3.3)
4. Describe the assessment of inguinal lymphadenopathy in gynaecological practice. (Linked to SLO 3.3)
5. Describe the signs of systemic disease relevant to a gynaecological presentation. (Linked to SLO 3.3)

3.3 Pelvic Examination: Positioning, Inspection, and Speculum Technique

3.3.1 Positioning and preparation for pelvic examination

Positioning for pelvic examination is typically the dorsal (lithotomy) position, with the woman lying supine, hips flexed and abducted, and feet supported, or, in some circumstances, the left lateral position, particularly used with a Sims' speculum or where the dorsal position is

laNET | ONLINE LEARNING VIDEO PLATFORM FOR POST-SECONDARY & HIGHER INSTITUTION STUDENTS

laetonline.com

uncomfortable or impractical, with the choice of position guided by the specific purpose of the examination and the woman's own comfort and preference wherever this is reasonably possible.

Immediately before the examination begins the clinician should confirm that consent remains current, that a chaperone has been offered and is present if desired, that appropriate privacy and draping are in place, and that all necessary equipment, including an appropriately sized speculum, adequate lighting, and lubricant, has been checked and is within immediate reach, avoiding any need to interrupt the examination once it has begun.

Fill in the blank: The typical position for pelvic examination is the dorsal or _____ position. Before the examination begins, the clinician should confirm consent remains _____ and that all equipment is within reach.

3.3.2 Inspection of the external genitalia

Inspection of the external genitalia precedes any instrumentation, systematically assessing the labia majora and minora, clitoris, urethral and vaginal openings, and perineum for any lesion, discoloration, swelling, discharge, or atrophic change, with any abnormality noted, described precisely, and, where appropriate, photographed with consent for documentation purposes.

Specific findings to actively look for include vulval skin changes suggestive of lichen sclerosus or other dermatological conditions, a Bartholin's gland swelling, genital warts or other lesions suggestive of infection, and signs of female genital mutilation where relevant, each requiring specific further assessment or referral as appropriate to the finding identified.

Fill in the blank: Inspection of the external genitalia should always precede any _____. Vulval skin changes suggestive of _____ sclerosus should be specifically looked for during inspection.

3.3.3 Speculum examination technique

Speculum examination uses either a bivalve Cusco's speculum (most commonly used, providing self-retaining visualisation of the cervix once opened) or a Sims' speculum (used in the left lateral position, particularly for assessing vaginal wall prolapse), inserted gently, with adequate lubrication, following the natural axis of the vagina, and opened slowly to allow visualisation of the cervix and vaginal walls with minimal discomfort to the woman.

Once the cervix is visualised it should be systematically assessed for colour, any visible lesion, discharge, contact bleeding, or the presence of a polyp, with cervical cytology or swabs taken at this point if clinically indicated, before the speculum is gently withdrawn while continuing to observe the vaginal walls for any abnormality not visible during insertion.

Fill in the blank: The most commonly used speculum, providing self-retaining visualisation of the cervix, is the _____ speculum. Once visualised, the cervix should be systematically assessed for colour, lesion, discharge, and contact _____.

lanetonline.com

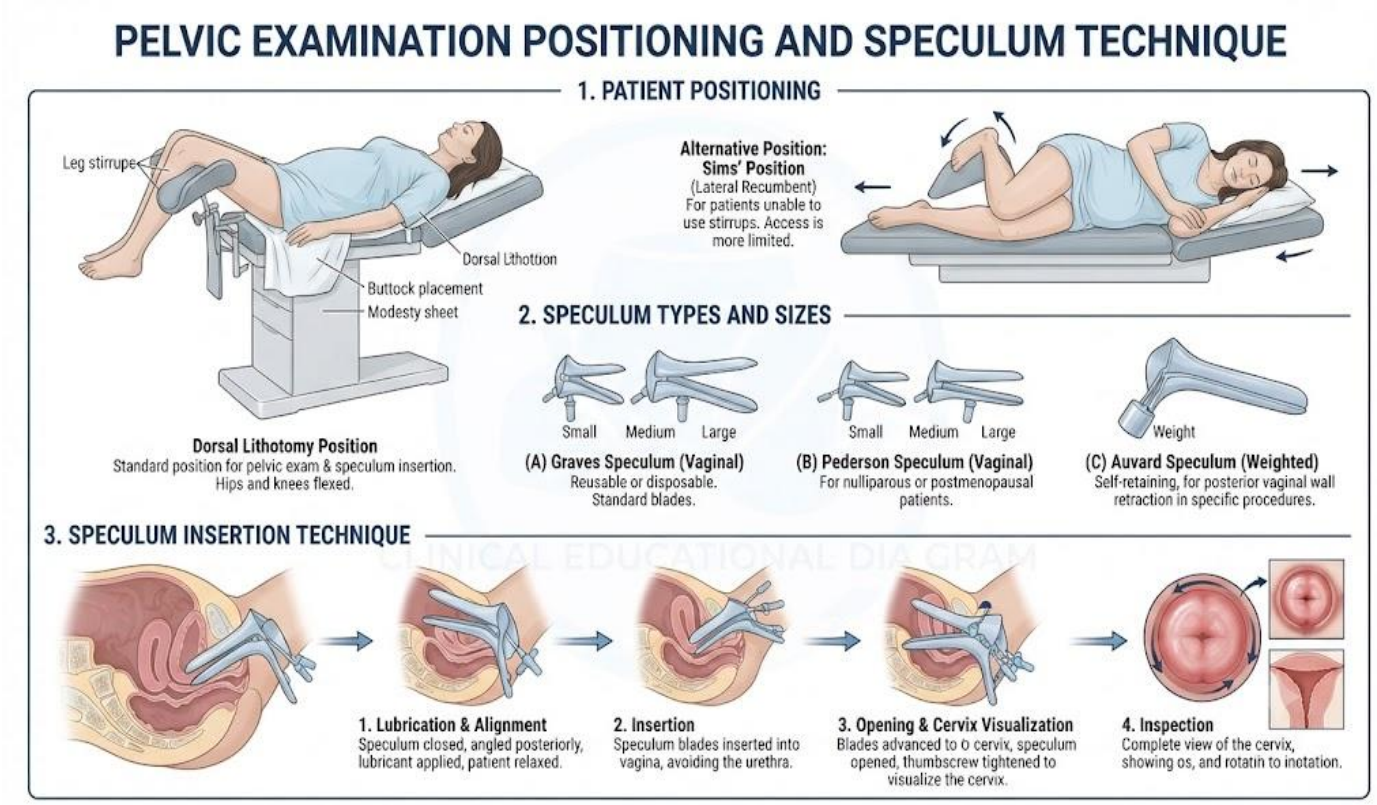

Figure 3.3: Positioning for pelvic examination and speculum insertion technique.

Pilot questions 3.3

1. Describe the positions used for pelvic examination and when each is appropriate. (Linked to SLO 3.4)
2. Describe the final preparation steps immediately before beginning a pelvic examination. (Linked to SLO 3.4)
3. Describe the systematic approach to inspecting the external genitalia. (Linked to SLO 3.5)
4. Compare the Cusco's and Sims' speculum and their indications. (Linked to SLO 3.5)
5. Describe the technique of speculum insertion and cervical assessment. (Linked to SLO 3.5)

3.4 Bimanual and Special Pelvic Examination Techniques

3.4.1 Bimanual pelvic examination technique

Bimanual examination is performed with two gloved, lubricated fingers of the examining hand inserted gently into the vagina while the other hand palpates the lower abdomen, first assessing the cervix for position, consistency, mobility, and any tenderness on movement (cervical excitation), before palpating the uterus for size, shape, position, mobility, and tenderness, and finally the adnexa for any mass, fullness, or tenderness.

Systematic technique and a consistent sequence, always performed in the same order regardless of the presenting complaint, reduce the risk of an important finding being missed, and gentle, unhurried technique throughout, with continuous attention to the woman's comfort and verbal or non-verbal cues of discomfort, remains essential even as the examiner's technical proficiency and confidence develop with increasing clinical experience.

Fill in the blank: Bimanual examination first assesses the cervix, then the _____, and finally the adnexa. A consistent examination sequence, performed the same way regardless of presenting complaint, reduces the risk of a missed _____.

3.4.2 Rectal and rectovaginal examination

Rectal examination is not a routine component of every gynaecological assessment but is specifically indicated when assessing posterior pelvic pathology, such as suspected rectovaginal endometriosis or a mass in the pouch of Douglas, and in the staging assessment of cervical or other pelvic malignancy, where it can provide information about parametrial or rectal wall involvement not otherwise accessible on vaginal examination alone.

Rectovaginal examination (with one finger simultaneously in the vagina and one in the rectum) allows more precise assessment of the rectovaginal septum, uterosacral ligaments, and pouch of Douglas than either examination performed alone, of particular value in the assessment of suspected deep infiltrating endometriosis, where nodularity or tenderness in this specific region is a characteristic examination finding.

Fill in the blank: Rectal examination is specifically indicated in the assessment of suspected rectovaginal _____. Rectovaginal examination allows precise assessment of the rectovaginal septum, uterosacral ligaments, and the pouch of _____.

3.4.3 Special examination techniques

Examination under anaesthesia is indicated when adequate assessment cannot be achieved in the awake patient because of pain, anxiety, or significant muscle guarding, or when a more thorough, detailed assessment is required before a planned surgical procedure, allowing complete relaxation of the abdominal and pelvic musculature and a considerably more accurate assessment of pelvic pathology than is often possible in the outpatient clinic setting.

Examination of a child with a suspected gynaecological concern requires a specifically adapted, gentle approach, generally avoiding internal examination wherever possible, using external inspection and, where indicated, specialist paediatric gynaecological equipment or imaging instead, always conducted with a parent or guardian present, and, given the potential for such

lanetonline.com

presentations to raise safeguarding considerations, with appropriate awareness of local safeguarding referral pathways throughout.

Fill in the blank: Examination under anaesthesia is indicated when adequate assessment cannot be achieved in the awake patient because of pain, anxiety, or significant muscle _____. Examination of a child requires a specifically adapted approach, generally avoiding _____ examination wherever possible.

Step / Technique	Key Details
Cervix	Assess position, mobility, consistency, and tenderness.
Uterus	Evaluate size, shape, position (anteverted/retroverted), mobility, and tenderness.
Adnexa	Palpate for masses, tenderness, or fullness in the adnexal regions.
Rectal Examination	Indicated for suspected rectal involvement, posterior pelvic masses, or endometriosis.
Rectovaginal Examination	Useful for assessing the pouch of Douglas, posterior uterine wall, and deep pelvic pathology.
Examination Under Anaesthesia	Indicated when pain limits examination, or for detailed assessment before surgery.

Box 3.4: Sequence of bimanual examination and indications for special examination techniques.

Pilot questions 3.4

1. Describe the technique and sequence of bimanual pelvic examination. (Linked to SLO 3.6)
2. Explain why a consistent examination sequence is important in bimanual examination. (Linked to SLO 3.6)
3. Describe the indications for rectal and rectovaginal examination. (Linked to SLO 3.7)
4. Describe the indications for examination under anaesthesia. (Linked to SLO 3.7)
5. Describe the adapted approach required when examining a child with a gynaecological concern. (Linked to SLO 3.7)

lanetonline.com

Series Summary

This Series has covered preparation, general inspection, and vital sign assessment, together with breast examination, followed by systemic examination relevant to gynaecology, including thyroid, abdominal, and lymph node assessment. It went on to examine pelvic examination positioning, inspection, and speculum technique, before concluding with bimanual pelvic examination and special techniques, including rectal, rectovaginal, and examination under anaesthesia.

You should now be able to describe preparation for gynaecological examination and demonstrate general inspection, vital sign, and breast assessment, demonstrate systemic examination relevant to gynaecology, describe positioning and demonstrate inspection and speculum technique, demonstrate bimanual pelvic examination, and describe rectal, rectovaginal, and special examination techniques (Linked to SLOs 3.1 to 3.7).

Glossary of Terms

1. **Acanthosis nigricans:** a velvety, hyperpigmented skin change often at the neck or axillae, associated with insulin resistance.
2. **Bimanual examination:** pelvic examination using two gloved fingers in the vagina and the other hand on the abdomen.
3. **Cusco's speculum:** a bivalve, self-retaining speculum, the most commonly used speculum in gynaecological examination.
4. **Examination under anaesthesia:** pelvic examination performed under anaesthesia to allow complete muscular relaxation and more accurate assessment.
5. **Lithotomy position:** the dorsal position used for pelvic examination, with hips flexed and abducted.
6. **Rectovaginal examination:** examination with one finger in the vagina and one in the rectum, used to assess the rectovaginal septum and pouch of Douglas.
7. **Sims' speculum:** a speculum used in the left lateral position, particularly for assessing vaginal wall prolapse.
8. **Triple assessment:** the combination of clinical examination, imaging, and pathology used to assess any new breast symptom.
9. **Cervical excitation:** pain elicited on movement of the cervix during bimanual examination.

lanetonline.com

10. **Lichen sclerosus:** a chronic inflammatory skin condition affecting the vulva, identifiable on inspection of the external genitalia.
11. **Pouch of Douglas:** the rectouterine pouch, the most dependent part of the female pelvic cavity, assessable on rectal or rectovaginal examination.
12. **Adnexa:** the fallopian tubes and ovaries, collectively, as assessed on bimanual pelvic examination.

Concept Check Questions [Series 3]

Objective questions

- Thorough preparation includes obtaining informed consent and offering a chaperone regardless of examiner _____.
- Thyroid palpation is typically performed from _____ the seated patient.
- A pelvic mass characteristically cannot be palpated from _____ on abdominal examination.
- The most commonly used speculum, providing self-retaining visualisation of the cervix, is the _____ speculum.
- Bimanual examination first assesses the cervix, then the _____, and finally the adnexa.

Short-answer questions

1. List the breast findings that should prompt urgent referral. (Linked to SLO 3.2)
2. Describe the assessment of inguinal lymphadenopathy in gynaecological practice. (Linked to SLO 3.3)
3. Compare the Cusco's and Sims' speculum and their indications. (Linked to SLO 3.5)
4. Explain why a consistent examination sequence is important in bimanual examination. (Linked to SLO 3.6)
5. Describe the indications for examination under anaesthesia. (Linked to SLO 3.7)

la-NET | ONLINE LEARNING VIDEO PLATFORM FOR POST-SECONDARY & HIGHER INSTITUTION STUDENTS

Long-answer questions

6. Describe the preparation and general examination performed before pelvic assessment, including breast and systemic examination. (Linked to SLO 3.1, SLO 3.2, SLO 3.3)
7. Describe the positioning, inspection, and speculum technique used in pelvic examination. (Linked to SLO 3.4, SLO 3.5)
8. Describe the technique of bimanual pelvic examination. (Linked to SLO 3.6)
9. Describe the indications and technique of rectal and rectovaginal examination. (Linked to SLO 3.7)
10. Describe the indications for examination under anaesthesia and the adapted approach to examining a child. (Linked to SLO 3.7)

Answers to Concept Check Questions [Series 3]

Objective questions

11. Gender.
12. Behind.
13. Below.
14. Cusco's.
15. Uterus.

Short-answer questions

16. A hard, irregular, fixed lump, skin dimpling, or nipple retraction or bloody discharge.
17. Careful palpation for size, consistency, tenderness, and mobility, with hard fixed nodes raising concern for malignant infiltration.
18. Cusco's is bivalve and commonly used for general visualisation; Sims' suits the left lateral position, particularly for prolapse assessment.
19. It reduces the risk of an important finding being missed, regardless of the presenting complaint.

lanetonline.com

20. When adequate assessment cannot be achieved in the awake patient because of pain, anxiety, or muscle guarding, or before planned surgery.

Long-answer questions

21. **Basic response:** Preparation for examination includes consent, chaperone, and equipment checks, followed by general inspection, vital signs, and breast examination where relevant.

Value-added response: Systemic examination, including thyroid, abdominal, and lymph node assessment, provides important clues before any pelvic examination begins.

22. **Basic response:** Pelvic examination begins with positioning and inspection of the external genitalia, followed by speculum examination to visualise the cervix and vaginal walls.

Value-added response: The Cusco's and Sims' specula each suit different positions and purposes, with technique adapted to minimise discomfort.

23. **Basic response:** Bimanual examination assesses the cervix, uterus, and adnexa in a consistent sequence using two gloved fingers and abdominal palpation.

Value-added response: Rectal, rectovaginal, and examination under anaesthesia are reserved for specific indications, including posterior pathology and inadequate awake assessment.

Answers to Pilot Questions [Series 3]

Part 3.1

1. Informed consent, explanation, chaperone offer, and ensuring privacy and equipment are ready before the woman undresses.
2. Demeanour, distress, gait, and obvious physical findings such as pallor or jaundice noted from the moment she enters.
3. Pulse, blood pressure, temperature, and, where indicated, respiratory rate and oxygen saturation, interpreted in clinical context.
4. Systematic inspection for asymmetry or skin changes, followed by palpation for a lump, tenderness, or nipple discharge.

lanetonline.com

5. Hard, irregular, fixed lump, skin dimpling, and nipple retraction or bloody discharge.

Part 3.2

6. Inspection for goitre, palpation from behind for size, consistency, and nodularity, and auscultation for a bruit if indicated.
7. Hirsutism, acne, and acanthosis nigricans, suggesting androgen excess or an underlying metabolic disorder.
8. Inspection, palpation, percussion, and auscultation, with palpation starting gently and away from any reported pain.
9. Careful palpation for size, consistency, tenderness, and mobility, with hard fixed nodes of particular concern.
10. Jaundice, peripheral oedema, and cachexia or unintentional weight loss, each warranting further assessment.

Part 3.3

11. Dorsal (lithotomy) or left lateral position, chosen according to the purpose of the examination and patient comfort.
12. Confirming consent remains current, chaperone presence if desired, adequate privacy and draping, and equipment checked and ready.
13. Systematic assessment of the labia, clitoris, urethral and vaginal openings, and perineum for any abnormality.
14. Cusco's is bivalve and self-retaining for general visualisation; Sims' is used in the left lateral position, particularly for prolapse.
15. Gentle insertion with lubrication along the vaginal axis, opened slowly, then systematic assessment of the cervix and vaginal walls.

Part 3.4

1. Two gloved fingers in the vagina assess the cervix, then the uterus, then the adnexa, with the other hand on the abdomen.

laNET | ONLINE LEARNING VIDEO PLATFORM FOR POST-SECONDARY & HIGHER INSTITUTION STUDENTS

2. A consistent sequence reduces the risk of an important finding being missed, regardless of the presenting complaint.
3. Suspected rectovaginal endometriosis, a mass in the pouch of Douglas, and staging assessment of pelvic malignancy.
4. Inadequate assessment in the awake patient because of pain, anxiety, or guarding, or before a planned surgical procedure.
5. A gentle, adapted approach generally avoiding internal examination, with a parent or guardian present and safeguarding awareness.

References and Attributions [Series 3]

Textual References

1. Hoffman, B. L., Schorge, J. O., Halvorson, L. M. et al. (2020). Williams Gynecology (4th ed.). McGraw Hill.
2. Talley, N. J. and O'Connor, S. (2017). Clinical Examination: A Systematic Guide to Physical Diagnosis (8th ed.). Elsevier.
3. Royal College of Obstetricians and Gynaecologists (2022). Gynaecological Examination: Guidance for Clinicians. RCOG Press.
4. General Medical Council (2020). Intimate Examinations and Chaperones. GMC.

Figures, Plates, Tables, and Boxes

1. Box 3.1: Essential preparation steps before gynaecological examination. AI-generated using the prompt: "Create a simple single-column reference box with an outside border titled Preparation for Gynaecological Examination, listing essential preparation steps. Clinical reference box style."
2. Table 3.2: Systemic examination findings relevant to gynaecological assessment. AI-generated using the prompt: "Create a clean reference table titled Systemic Examination Findings Relevant to Gynaecology, listing findings and their clinical significance. Simple clinical reference table style with outside border."
3. Figure 3.3: Positioning for pelvic examination and speculum insertion technique. AI-generated using the prompt: "Create a professional medical diagram titled Pelvic

lanetonline.com

Examination Positioning and Speculum Technique, showing patient positions and speculum types with insertion technique. Clean clinical educational diagram style."

4. Box 3.4: Sequence of bimanual examination and indications for special examination techniques. AI-generated using the prompt: "Create a simple single-column reference box with an outside border titled Bimanual Examination Sequence and Special Techniques, listing the examination sequence and special indications. Clinical reference box style."

lanetonline.com

Course code: OBG 507

Course title: Gynaecological Clinic and Simulation Training

Course credit load: 2 Units

Series 4: Clinic-Based Procedures and Investigations

- **Part 4.1: Cervical Cytology and Screening**
  - Sub Part 4.1.1: Pap smear technique and indications
  - Sub Part 4.1.2: Interpretation and follow-up of cervical cytology results
  - Sub Part 4.1.3: HPV testing and cervical screening programmes
- **Part 4.2: Microbiological Sampling**
  - Sub Part 4.2.1: High vaginal swab technique
  - Sub Part 4.2.2: Endocervical and other microbiological swabs
  - Sub Part 4.2.3: Interpretation of microbiological results
- **Part 4.3: Other Clinic-Based Diagnostic Procedures**
  - Sub Part 4.3.1: Endometrial sampling (pipelle biopsy)
  - Sub Part 4.3.2: Vulval and cervical biopsy
  - Sub Part 4.3.3: Point-of-care testing in the gynaecological clinic
- **Part 4.4: Clinic-Based Therapeutic Procedures**
  - Sub Part 4.4.1: Intrauterine device insertion and removal
  - Sub Part 4.4.2: Bartholin's cyst drainage and other minor procedures
  - Sub Part 4.4.3: Preparing and consenting patients for clinic-based procedures

Introduction

In the last Series, we explored general and pelvic examination technique. Many gynaecological consultations, however, extend beyond history and examination alone into the practical

laetonline.com

procedures and investigations performed within the clinic itself: a cervical smear, a swab to identify infection, a small tissue biopsy, or a therapeutic procedure such as an intrauterine device insertion. This Series turns to these clinic-based procedures and investigations, the practical, hands-on skills that so often complete a gynaecological assessment and, frequently, its management, all within a single outpatient visit.

The aim of this Series is to equip you with the knowledge and practical skill to perform and interpret common clinic-based gynaecological procedures and investigations.

We shall commence this Series by examining cervical cytology and screening, including the role of HPV testing. Next, we will consider microbiological sampling, including high vaginal and endocervical swabs. Following that, our attention turns to other clinic-based diagnostic procedures, including endometrial and tissue biopsy sampling and point-of-care testing. Finally, we will conclude by examining clinic-based therapeutic procedures, including intrauterine device insertion and Bartholin's cyst drainage, and the principles of preparing and consenting patients for these procedures.

Series Learning Outcomes

Upon completing this Series, you should be able to:

- **SLO 4.1:** demonstrate pap smear technique and describe cervical screening,
- **SLO 4.2:** describe the interpretation and follow-up of cervical cytology and the role of HPV testing,
- **SLO 4.3:** demonstrate high vaginal swab and other microbiological sampling technique,
- **SLO 4.4:** describe other clinic-based diagnostic procedures, including endometrial and tissue biopsy sampling,
- **SLO 4.5:** describe the role and quality assurance of point-of-care testing in the gynaecological clinic,
- **SLO 4.6:** describe clinic-based therapeutic procedures, including IUD insertion and Bartholin's cyst drainage, and
- **SLO 4.7:** describe the principles of preparing and consenting patients for clinic-based procedures.

4.1 Cervical Cytology and Screening

4.1.1 Pap smear technique and indications

laetonline.com

Cervical cytology (Pap smear) is a screening test for pre-malignant and malignant change of the cervix, performed by sampling cells from the transformation zone, the site where columnar and squamous epithelium meet and where the great majority of cervical dysplasia and carcinoma arise, using a specifically designed sampling device (such as a cervical brush) rotated against the cervix under direct visualisation with a speculum in place.

Correct technique requires clear visualisation of the entire cervix before sampling, adequate rotation of the sampling device to capture cells from the full circumference of the transformation zone, and prompt transfer of the sample into an appropriate liquid-based cytology medium, with technique errors, including inadequate sampling or poor cell preservation, being a recognised and largely avoidable cause of an inadequate or unsatisfactory result requiring the test to be repeated.

Fill in the blank: Cervical cytology samples cells from the transformation zone, where columnar and squamous _____ meet. Technique errors are a recognised and largely avoidable cause of an inadequate or _____ result.

4.1.2 Interpretation and follow-up of cervical cytology results

Cervical cytology results are reported using a standardised classification system describing the degree of any dyskaryosis identified (borderline, low-grade, or high-grade), each carrying a different implication for the likely presence of underlying cervical intraepithelial neoplasia and, correspondingly, a different recommended follow-up pathway, ranging from routine recall at the standard screening interval to prompt referral for colposcopy.

Clear, structured communication of cytology results to the patient, including what the result means, what happens next, and, where relevant, an honest acknowledgement of any uncertainty, is an essential component of the screening process, as an unclear or poorly explained abnormal result can cause considerable, sometimes disproportionate anxiety, and inadequate understanding may lead to a woman failing to attend recommended follow-up.

Fill in the blank: Cervical cytology results describe the degree of dyskaryosis as borderline, low-grade, or _____. Clear communication of results is essential, as an unclear result can cause disproportionate _____.

4.1.3 HPV testing and cervical screening programmes

High-risk human papillomavirus (HPV) testing is now used as the primary screening test in many modern cervical screening programmes, given the established causal role of persistent high-risk HPV infection in cervical carcinogenesis, with cytology then performed as a secondary, triage test only in women who test HPV positive, an approach shown to be more sensitive for detecting significant cervical disease than cytology alone.

Structured screening programmes define the age at which screening begins, the interval between routine screening tests, and the age at which screening ceases, based on population-level evidence of risk and benefit, and understanding the rationale behind these programme

lanetonline.com

parameters, rather than viewing them as arbitrary rules, helps clinicians explain and encourage genuine engagement with screening among the women in their care.

Fill in the blank: High-risk HPV testing is used as the primary test in many modern screening programmes, with cytology as a secondary _____ test. HPV-primary screening is more sensitive for detecting significant cervical disease than _____ alone.

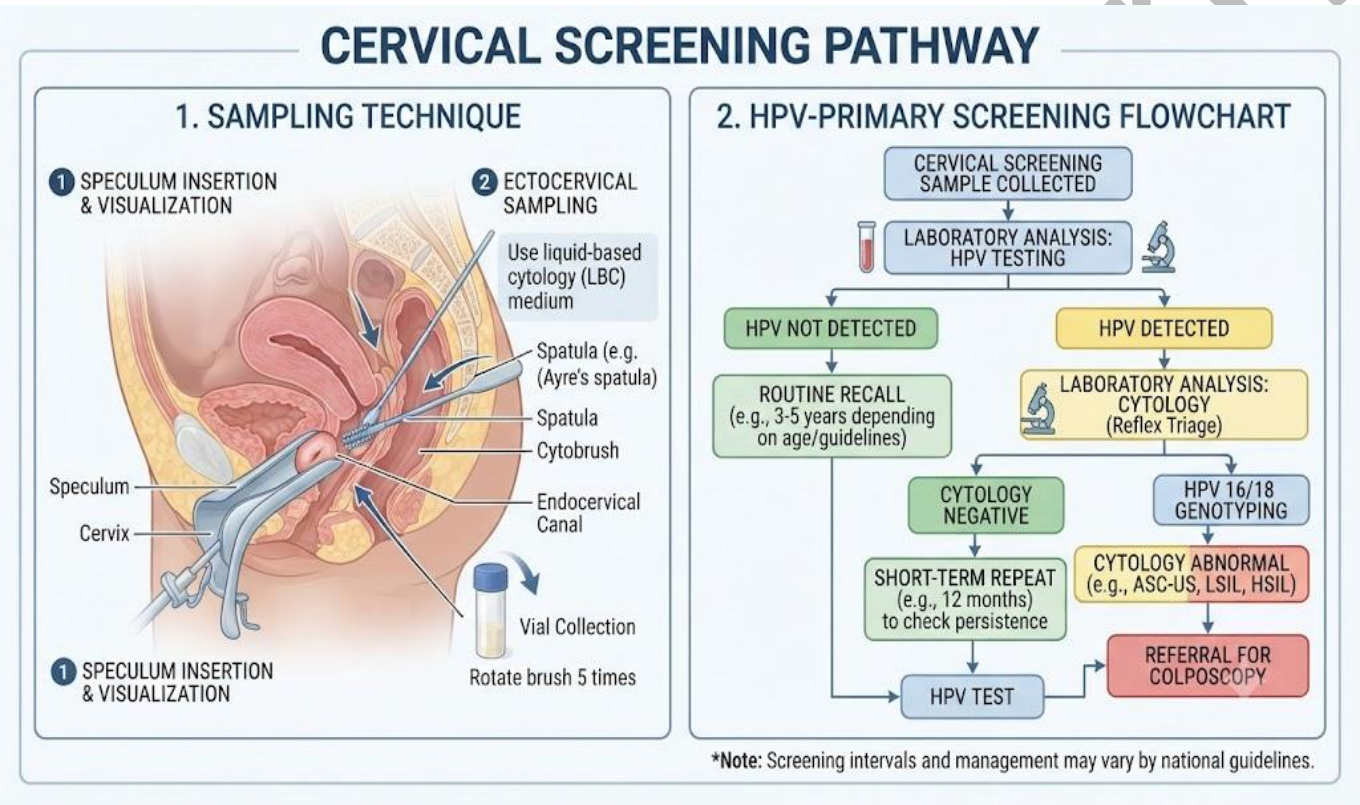

Figure 4.1: Cervical cytology sampling technique and the HPV-primary screening pathway.

Pilot questions 4.1

- Describe the technique of taking a cervical cytology sample. (Linked to SLO 4.1)
- Explain why the transformation zone is specifically targeted during cervical sampling. (Linked to SLO 4.1)
- Describe the classification used to report cervical cytology results. (Linked to SLO 4.2)
- Explain why clear communication of cytology results to the patient is essential. (Linked to SLO 4.2)
- Describe the role of HPV testing in modern cervical screening programmes. (Linked to SLO 4.2)

4.2 Microbiological Sampling

4.2.1 High vaginal swab technique

A high vaginal swab is taken to identify infective causes of abnormal vaginal discharge or other suggestive symptoms, obtained under direct visualisation with a speculum in place, sampling from the posterior fornix or lateral vaginal walls where discharge tends to pool, using a sterile swab that is then placed into appropriate transport medium and labelled clearly before prompt transfer to the laboratory.

Correct technique avoids contamination of the swab by external skin or vulval flora, which could confound the microbiological result, and the swab should be taken before any other examination manoeuvre or treatment that might dilute or otherwise alter the sample, such as application of lubricant gel, which can itself interfere with accurate microbiological culture and yield a false-negative result.

Fill in the blank: A high vaginal swab samples from the posterior fornix or lateral vaginal walls where discharge tends to _____. The swab should be taken before application of lubricant gel, which can interfere with accurate microbiological _____.

4.2.2 Endocervical and other microbiological swabs

Endocervical swabs are specifically indicated when chlamydia or gonorrhoea infection is suspected, obtained by inserting a swab a short distance into the endocervical canal and rotating gently to sample columnar epithelial cells, a technique distinct from the high vaginal swab, which samples the vaginal walls rather than the cervix itself, and both types of swab may be indicated together depending on the clinical presentation and suspected organisms.

Nucleic acid amplification tests (NAATs) have increasingly replaced traditional culture-based methods for detecting chlamydia and gonorrhoea, offering considerably higher sensitivity, and can often be performed on a self-collected vulvovaginal swab or first-catch urine sample, an important development that has improved accessibility and acceptability of screening for sexually transmitted infection, particularly in settings or circumstances where a full speculum examination is not readily available or acceptable to the patient.

Fill in the blank: Endocervical swabs sample columnar epithelial cells and are specifically indicated when _____ or gonorrhoea infection is suspected. Nucleic acid amplification tests offer considerably higher _____ than traditional culture-based methods.

4.2.3 Interpretation of microbiological results

Interpreting microbiological results requires understanding that a positive result does not always equate to clinically significant infection, as some organisms identified, particularly on vaginal swab, may represent normal commensal flora rather than genuine pathogens, meaning results should always be interpreted in the context of the woman's symptoms and examination findings rather than treated in complete isolation.

la-net.com

A negative microbiological result similarly does not entirely exclude infection, particularly if the sample was taken incorrectly, too soon after exposure for the organism to be reliably detectable, or after recent antibiotic use, and a woman with a strongly suggestive clinical picture but a negative test result may still warrant empirical treatment or repeat testing rather than automatic reassurance based on the negative result alone.

Fill in the blank: A positive microbiological result does not always equate to clinically significant infection, as some organisms may represent normal _____ flora. A woman with a strongly suggestive clinical picture but a negative test may still warrant _____ treatment or repeat testing.

Swab Type	Sampling Site	Target Organisms	Technique
High Vaginal Swab	Posterior fornix of the vagina	Candida, bacterial vaginosis organisms, Trichomonas vaginalis	Insert sterile swab into posterior fornix, rotate gently, avoid contamination.
Endocervical Swab	Endocervical canal	Chlamydia trachomatis, Neisseria gonorrhoeae	Insert swab into cervical os, rotate within canal to collect epithelial cells.

Table 4.2: Comparison of high vaginal and endocervical swab technique and indications.

Pilot questions 4.2

1. Describe the technique and purpose of a high vaginal swab. (Linked to SLO 4.3)
2. Explain why the swab should be taken before application of lubricant gel. (Linked to SLO 4.3)
3. Distinguish endocervical swab technique from high vaginal swab technique. (Linked to SLO 4.3)
4. Describe the advantages of nucleic acid amplification testing for chlamydia and gonorrhoea. (Linked to SLO 4.3)
5. Explain why microbiological results should be interpreted in clinical context rather than in isolation. (Linked to SLO 4.3)

4.3 Other Clinic-Based Diagnostic Procedures

4.3.1 Endometrial sampling (pipelle biopsy)

Endometrial sampling by pipelle biopsy is an outpatient procedure used to investigate abnormal uterine bleeding, particularly postmenopausal bleeding, in which a narrow, flexible

laetonline.com

plastic device is passed through the cervix into the uterine cavity, and a small tissue sample obtained by gentle suction as the device is withdrawn and rotated, providing histological material for laboratory analysis without the need for cervical dilatation or anaesthesia in the great majority of cases.

Limitations of pipelle biopsy include a recognised false-negative rate, as the sample obtained represents only a portion of the endometrial cavity, meaning persistent or recurrent abnormal bleeding despite a normal pipelle result should prompt further investigation, typically with hysteroscopy, rather than automatic reassurance, given the clinical importance of not missing significant endometrial pathology in this circumstance.

Fill in the blank: Pipelle biopsy obtains a tissue sample by gentle _____ as the device is withdrawn and rotated. Persistent bleeding despite a normal pipelle result should prompt further investigation with _____ rather than automatic reassurance.

4.3.2 Vulval and cervical biopsy

Vulval biopsy is indicated for any persistent, unexplained vulval lesion, or one with features suspicious for malignancy, performed under local anaesthesia using a punch biopsy technique, with the specific site selected to include both the abnormal area and, where possible, adjacent normal tissue to aid histological comparison and interpretation by the pathologist.

Cervical biopsy (either a targeted punch biopsy taken during colposcopy, or a larger excisional biopsy such as loop electrosurgical excision procedure) is performed to obtain histological confirmation of suspected cervical dysplasia or malignancy identified on cytology or direct visualisation, with the specific technique chosen according to the clinical suspicion and the extent of the visible or suspected abnormality.

Fill in the blank: Vulval biopsy is performed under local anaesthesia using a _____ biopsy technique. Cervical biopsy may be a targeted punch biopsy during colposcopy or a larger _____ biopsy such as LEEP.

4.3.3 Point-of-care testing in the gynaecological clinic

Point-of-care testing (urine pregnancy testing, urinalysis, and rapid glucose or haemoglobin testing) provides immediate results within the consultation itself, allowing real-time clinical decision-making without the delay associated with sending a sample to a central laboratory, a particularly valuable capability in the acute or emergency gynaecological setting, where a delayed result could meaningfully affect the timeliness of appropriate management.

Quality assurance of point-of-care testing, including correct storage and handling of testing kits, adherence to the manufacturer's specified technique, and regular staff training and competency assessment, is essential to ensure the reliability and clinical trustworthiness of results generated within the clinic itself, given that these tests are typically performed by a wider range of clinical staff than those used in a formally regulated central laboratory setting.

laNETonline.com

Fill in the blank: Point-of-care testing provides immediate results within the consultation, avoiding the delay of sending a sample to a central _____. Quality assurance of point-of-care testing includes correct storage, adherence to technique, and staff _____.

Procedure	Indication
Pipelle Biopsy	Sampling of endometrium for evaluation of abnormal uterine bleeding or suspected endometrial pathology.
Vulval Biopsy	Diagnosis of vulval lesions such as lichen sclerosus, neoplasia, or unexplained chronic changes.
Cervical Biopsy	Histological confirmation of abnormal cervical cytology or colposcopic findings.
Point-of-Care Testing	Rapid diagnosis of infections (e.g., chlamydia, gonorrhoea, trichomoniasis) or pregnancy status.

Box 4.3: Summary of clinic-based diagnostic procedures and their indications.

Pilot questions 4.3

1. Describe the technique and indication for pipelle biopsy. (Linked to SLO 4.4)
2. Explain the limitations of pipelle biopsy and when further investigation is indicated. (Linked to SLO 4.4)
3. Describe the indications and technique for vulval biopsy. (Linked to SLO 4.4)
4. Compare targeted punch biopsy and excisional cervical biopsy. (Linked to SLO 4.4)
5. Describe the value and quality assurance requirements of point-of-care testing in the gynaecological clinic. (Linked to SLO 4.5)

4.4 Clinic-Based Therapeutic Procedures

4.4.1 Intrauterine device insertion and removal

Intrauterine device (IUD) insertion is a clinic-based procedure performed under aseptic technique, involving bimanual examination to assess uterine size and position, insertion of a speculum, cleaning of the cervix, and careful, gentle passage of the device through the cervical canal into the uterine cavity using a specifically designed insertion device, with uterine sounding beforehand to confirm cavity length and reduce the risk of perforation.

IUD removal is generally straightforward, performed by gently grasping the visible threads with forceps under direct visualisation and applying steady traction, though a device with threads not visible or palpable requires further investigation, typically ultrasound, to confirm the device's

la-NET | ONLINE LEARNING VIDEO PLATFORM FOR POST-SECONDARY & HIGHER INSTITUTION STUDENTS

location before any attempt at removal, given the small but genuine risk of uterine perforation or device migration that this specific finding can occasionally indicate.

Fill in the blank: IUD insertion involves uterine sounding beforehand to confirm cavity length and reduce the risk of _____. A device with threads not visible or palpable requires further investigation, typically _____, before any attempt at removal.

4.4.2 Bartholin's cyst drainage and other minor procedures

Bartholin's cyst or abscess drainage in the clinic setting is generally performed by Word catheter insertion, in which a small incision is made into the cyst or abscess, the contents drained, and a small balloon-tipped catheter inserted and left in place for several weeks to allow formation of a permanent epithelialised drainage tract, an approach well suited to the outpatient clinic given its relative simplicity and the ability to perform it under local anaesthesia.

Other minor clinic-based procedures include cryotherapy for cervical intraepithelial neoplasia (destroying abnormal cervical tissue by freezing), removal of small, benign vulval or cervical polyps, and marsupialisation of a Bartholin's cyst under local anaesthesia, each requiring appropriate training and competency assessment before independent practice, given the genuine, if generally low, risk of complication associated with any procedural intervention.

Fill in the blank: Word catheter insertion for Bartholin's cyst allows formation of a permanent _____ drainage tract over several weeks. Cryotherapy for cervical intraepithelial neoplasia destroys abnormal cervical tissue by _____.

4.4.3 Preparing and consenting patients for clinic-based procedures

Preparing a patient for any clinic-based procedure includes clear explanation of the indication, what the procedure will involve, expected discomfort and how it will be managed, likely duration, and anticipated recovery, delivered in advance of the day of the procedure wherever practically possible, allowing the woman genuine time to consider the information and ask questions before providing consent.

Informed consent for a clinic-based procedure specifically covers the procedure's purpose, the alternatives available (including declining the procedure altogether), and the specific risks relevant to that particular procedure, with written consent generally obtained for more invasive procedures such as IUD insertion or biopsy, and careful, contemporaneous documentation of the consent discussion and the procedure itself an essential component of safe, professional clinic-based practice.

Fill in the blank: Preparing a patient for a clinic-based procedure includes explanation of indication, expected discomfort, duration, and anticipated _____. Informed consent covers the procedure's purpose, alternatives, and specific _____ relevant to that procedure.

laNetOnline.com

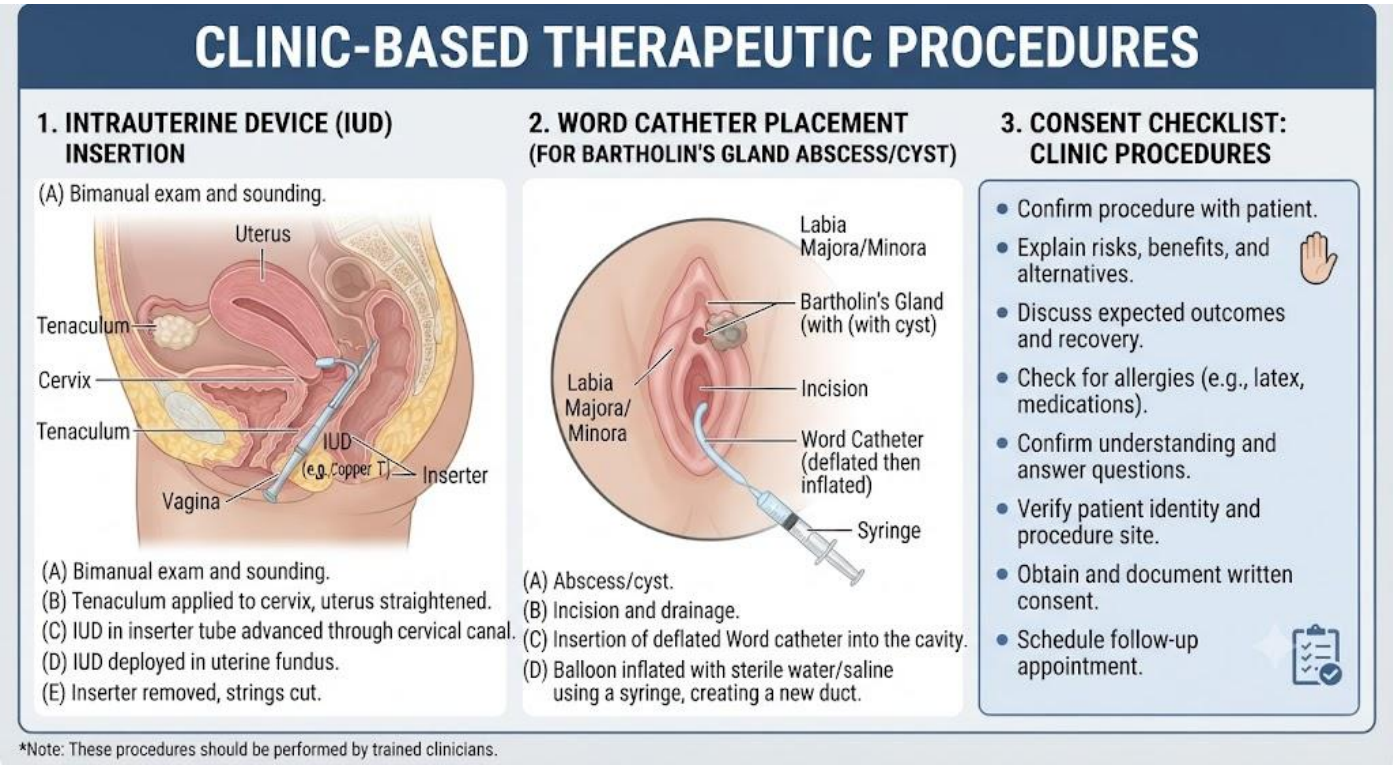

Figure 4.4: IUD insertion, Bartholin's cyst drainage, and the procedural consent checklist.

Pilot questions 4.4

1. Describe the technique of IUD insertion. (Linked to SLO 4.6)
2. Describe the management of an IUD with threads not visible or palpable. (Linked to SLO 4.6)
3. Describe the technique of Bartholin's cyst drainage using a Word catheter. (Linked to SLO 4.6)
4. Describe the components of preparing a patient for a clinic-based procedure. (Linked to SLO 4.7)
5. Describe the components of informed consent specific to a clinic-based procedure. (Linked to SLO 4.7)

lanetonline

Series Summary

This Series has covered cervical cytology and screening, including the role of HPV testing, followed by microbiological sampling, including high vaginal and endocervical swabs. It went on to examine other clinic-based diagnostic procedures, including endometrial and tissue biopsy sampling and point-of-care testing, before concluding with clinic-based therapeutic procedures, including intrauterine device insertion and Bartholin's cyst drainage, and the principles of patient preparation and consent.

You should now be able to demonstrate pap smear technique and describe cervical screening, describe the interpretation and follow-up of cytology and HPV testing, demonstrate microbiological sampling technique, describe other clinic-based diagnostic procedures and point-of-care testing, describe clinic-based therapeutic procedures, and describe the principles of patient preparation and consent (Linked to SLOs 4.1 to 4.7).

Glossary of Terms

1. **Colposcopy:** direct magnified visualisation of the cervix, used to further assess an abnormal cervical cytology result.
2. **Cryotherapy:** destruction of abnormal cervical tissue by freezing, a clinic-based treatment for cervical intraepithelial neoplasia.
3. **Dyskaryosis:** abnormal nuclear changes identified on cervical cytology, graded as borderline, low-grade, or high-grade.
4. **High vaginal swab:** a swab sample taken from the posterior fornix or lateral vaginal walls to identify infective causes of discharge.
5. **Nucleic acid amplification test (NAAT):** a highly sensitive molecular test used to detect chlamydia and gonorrhoea.
6. **Pipelle biopsy:** an outpatient method of endometrial sampling using a narrow, flexible device, used to investigate abnormal uterine bleeding.
7. **Point-of-care testing:** diagnostic testing performed within the consultation itself, providing immediate results.
8. **Transformation zone:** the site where columnar and squamous epithelium meet on the cervix, the origin of most cervical dysplasia.
9. **Uterine sounding:** measurement of uterine cavity length before IUD insertion to reduce the risk of perforation.

lanetonline.com

10. **Word catheter:** a small balloon-tipped catheter used to maintain drainage of a Bartholin's cyst or abscess.
11. **Loop electrosurgical excision procedure (LEEP):** an excisional technique used to treat confirmed high-grade cervical dysplasia.
12. **Punch biopsy:** a technique for obtaining a small, full-thickness tissue sample, used for vulval or targeted cervical biopsy.

Concept Check Questions [Series 4]

Objective questions

- Technique errors are a recognised and largely avoidable cause of an inadequate or _____ cervical cytology result.
- High-risk HPV testing is used as the primary test in many modern screening programmes, with cytology as a secondary _____ test.
- A high vaginal swab should be taken before application of _____ gel, which can interfere with microbiological culture.
- Persistent bleeding despite a normal pipelle result should prompt further investigation with _____.
- A device with threads not visible or palpable requires further investigation, typically _____, before any attempt at removal.

Short-answer questions

1. Explain why clear communication of cytology results to the patient is essential. (Linked to SLO 4.2)
2. Distinguish endocervical swab technique from high vaginal swab technique. (Linked to SLO 4.3)
3. Explain the limitations of pipelle biopsy and when further investigation is indicated. (Linked to SLO 4.4)
4. Describe the value and quality assurance requirements of point-of-care testing in the gynaecological clinic. (Linked to SLO 4.5)

lanetonline.com

5. Describe the components of informed consent specific to a clinic-based procedure. (Linked to SLO 4.7)

Long-answer questions

6. Describe the technique and interpretation of cervical cytology and the role of HPV testing. (Linked to SLO 4.1, SLO 4.2)
7. Describe the technique and interpretation of high vaginal and endocervical swabs. (Linked to SLO 4.3)
8. Describe the clinic-based diagnostic procedures used to investigate abnormal uterine bleeding and vulval or cervical lesions. (Linked to SLO 4.4)
9. Describe the technique of intrauterine device insertion and Bartholin's cyst drainage. (Linked to SLO 4.6)
10. Describe the principles of preparing and consenting patients for clinic-based procedures. (Linked to SLO 4.7)

Answers to Concept Check Questions [Series 4]

Objective questions

11. Unsatisfactory.
12. Triage.
13. Lubricant.
14. Hysteroscopy.
15. Ultrasound.

Short-answer questions

16. An unclear result can cause disproportionate anxiety, and inadequate understanding may lead to failure to attend recommended follow-up.
17. Endocervical swab samples the endocervical canal for chlamydia or gonorrhoea; high vaginal swab samples the vaginal walls for general infective causes.

laNET | ONLINE LEARNING VIDEO PLATFORM FOR POST-SECONDARY & HIGHER INSTITUTION STUDENTS

laetonline.com

18. The sample represents only a portion of the endometrial cavity, so persistent bleeding despite a normal result should prompt hysteroscopy.
19. It provides immediate results without laboratory delay, but requires correct storage, adherence to technique, and staff training for reliability.
20. Explanation of the procedure's purpose, available alternatives including declining, and the specific risks relevant to that procedure.

Long-answer questions

21. **Basic response:** Cervical cytology samples the transformation zone and is reported by degree of dyskaryosis, with HPV testing now used as the primary screening test in many programmes.

Value-added response: Clear communication of results is essential, as unclear results can cause disproportionate anxiety or lead to non-attendance at follow-up.

22. **Basic response:** High vaginal swabs sample the vaginal walls for general infection, while endocervical swabs specifically target chlamydia and gonorrhoea.

Value-added response: Results must be interpreted in clinical context, as some organisms are commensal and negative results do not always exclude infection.

23. **Basic response:** Pipelle biopsy investigates abnormal bleeding via suction sampling, while vulval and cervical biopsy provide histological confirmation of suspicious lesions.

Value-added response: Persistent symptoms despite a normal pipelle result should prompt hysteroscopy rather than reassurance, given the recognised false-negative rate.

Answers to Pilot Questions [Series 4]

Part 4.1

1. A sampling device is rotated against the cervix under direct visualisation to capture cells from the transformation zone.
2. The transformation zone is where most cervical dysplasia and carcinoma arise, making it the focus of screening.

laneonline.com

3. Borderline, low-grade, or high-grade dyskaryosis, each with a different recommended follow-up pathway.
4. An unclear result can cause disproportionate anxiety and may lead to failure to attend recommended follow-up.
5. HPV is used as the primary test, with cytology performed as a secondary triage test only in HPV-positive women.

Part 4.2

6. Sampling from the posterior fornix or lateral vaginal walls under direct visualisation, to identify infective causes of discharge.
7. Lubricant gel can interfere with accurate microbiological culture and yield a false-negative result.
8. Endocervical swab samples the endocervical canal for chlamydia and gonorrhoea, unlike the vaginal wall sampling of a high vaginal swab.
9. NAATs offer considerably higher sensitivity and can often use self-collected or urine samples, improving accessibility.
10. Some organisms are normal commensal flora, so results should be interpreted alongside symptoms and examination findings.

Part 4.3

11. A narrow flexible device is passed into the uterine cavity and a small sample obtained by suction as it is withdrawn.
12. The sample represents only part of the cavity, so persistent bleeding despite a normal result warrants hysteroscopy.
13. Punch biopsy under local anaesthesia, including both abnormal and adjacent normal tissue for comparison.
14. Targeted punch biopsy samples a specific area during colposcopy; excisional biopsy such as LEEP removes a larger area of tissue.
15. It provides immediate results without laboratory delay, but requires correct storage, technique adherence, and staff training for reliability.

lanetonline.com

Part 4.4

1. Bimanual examination, uterine sounding, and careful passage of the device through the cervix using an insertion device.
2. Further investigation, typically ultrasound, is needed to confirm device location before any attempt at removal.
3. A small incision drains the cyst, and a balloon-tipped catheter is left in place for weeks to form a permanent tract.
4. Explanation of indication, procedure details, expected discomfort, duration, and anticipated recovery, given in advance where possible.
5. The procedure's purpose, available alternatives including declining, and the specific risks relevant to that procedure.

References and Attributions [Series 4]

Textual References

1. Hoffman, B. L., Schorge, J. O., Halvorson, L. M. et al. (2020). Williams Gynecology (4th ed.). McGraw Hill.
2. World Health Organization (2021). WHO Guideline for Screening and Treatment of Cervical Pre-Cancer Lesions for Cervical Cancer Prevention (2nd ed.). WHO Press.
3. Faculty of Sexual and Reproductive Healthcare (2015). Intrauterine Contraception. FSRH Clinical Guideline.
4. Royal College of Obstetricians and Gynaecologists (2022). Gynaecological Examination: Guidance for Clinicians. RCOG Press.

Figures, Plates, Tables, and Boxes

lanetonline.com

1. Figure 4.1: Cervical cytology sampling technique and the HPV-primary screening pathway. AI-generated using the prompt: "Create a professional medical diagram titled Cervical Screening Pathway, showing sampling technique and the HPV-primary screening flowchart. Clean clinical educational diagram style."
2. Table 4.2: Comparison of high vaginal and endocervical swab technique and indications. AI-generated using the prompt: "Create a clean reference table titled High Vaginal versus Endocervical Swab, comparing sampling site, target organisms, and technique. Simple clinical reference table style with outside border."
3. Box 4.3: Summary of clinic-based diagnostic procedures and their indications. AI-generated using the prompt: "Create a simple single-column reference box with an outside border titled Clinic-Based Diagnostic Procedures, listing key procedures with a one-line indication each. Clinical reference box style."
4. Figure 4.4: IUD insertion, Bartholin's cyst drainage, and the procedural consent checklist. AI-generated using the prompt: "Create a professional medical diagram titled Clinic-Based Therapeutic Procedures, showing IUD insertion, Word catheter placement, and a consent checklist panel. Clean clinical educational diagram style."

lanetonline.com

Course code: OBG 507

Course title: Gynaecological Clinic and Simulation Training

Course credit load: 2 Units

Series 5: Advanced Diagnostic and Surgical Techniques

- **Part 5.1: Colposcopy**
  - Sub Part 5.1.1: Indications and principles of colposcopy
  - Sub Part 5.1.2: Colposcopic technique and findings
  - Sub Part 5.1.3: Colposcopy-directed biopsy and management decisions
- **Part 5.2: Cryosurgery**
  - Sub Part 5.2.1: Principles and mechanism of cryosurgery
  - Sub Part 5.2.2: Indications and technique of cervical cryosurgery
  - Sub Part 5.2.3: Complications and follow-up after cryosurgery
- **Part 5.3: Hysteroscopy**
  - Sub Part 5.3.1: Indications and principles of hysteroscopy
  - Sub Part 5.3.2: Diagnostic hysteroscopy technique
  - Sub Part 5.3.3: Operative hysteroscopy and complications
- **Part 5.4: Laparoscopy**
  - Sub Part 5.4.1: Indications and principles of laparoscopy
  - Sub Part 5.4.2: Laparoscopic technique and entry methods
  - Sub Part 5.4.3: Complications of laparoscopy and simulation training

lanetonline.com

Introduction

In the last Series, we explored clinic-based procedures and investigations. We conclude this course, and this journey through Gynaecological Clinic and Simulation Training, by turning to

the advanced diagnostic and surgical techniques that extend beyond the routine outpatient clinic: colposcopy, cryosurgery, hysteroscopy, and laparoscopy. These are technically demanding skills, and the simulation-based approach woven throughout this course finds its fullest expression here, where deliberate, repeated practice in a safe environment genuinely matters before these techniques are ever applied to a real patient.

The aim of this Series is to equip you with the knowledge of the indications, technique, and complications of colposcopy, cryosurgery, hysteroscopy, and laparoscopy, and the role of simulation in developing these advanced skills.

We shall commence this Series by examining colposcopy, its indications, technique, and directed biopsy. Next, we will consider cryosurgery, its principles, indications, and complications. Following that, our attention turns to hysteroscopy, both diagnostic and operative. Finally, we will conclude by examining laparoscopy, its technique, complications, and the role of simulation-based training in developing these advanced surgical skills, bringing this course to a close.

Series Learning Outcomes

Upon completing this Series, you should be able to:

- **SLO 5.1:** describe the indications and principles of colposcopy,
- **SLO 5.2:** describe colposcopic technique, findings, and directed biopsy,
- **SLO 5.3:** describe the principles, indications, and technique of cervical cryosurgery,
- **SLO 5.4:** describe the indications and technique of diagnostic hysteroscopy,
- **SLO 5.5:** describe operative hysteroscopy and its complications,
- **SLO 5.6:** describe the indications and technique of laparoscopy, and
- **SLO 5.7:** describe the complications of laparoscopy and the role of simulation training in developing advanced surgical skills.

5.1 Colposcopy

5.1.1 Indications and principles of colposcopy

Colposcopy is direct, magnified visualisation of the cervix, vagina, and vulva using a specialised binocular instrument, indicated principally following an abnormal cervical screening result to further characterise the extent and severity of any cervical abnormality, and, less commonly, in

laNETonline.com

the investigation of post-coital bleeding, a visible cervical lesion, or suspected lower genital tract intraepithelial neoplasia identified on other grounds.

The underlying principle of colposcopy is that abnormal, dysplastic cervical epithelium reacts differently to the application of specific solutions compared with normal epithelium, most notably becoming visibly whiter (acetowhite change) following application of dilute acetic acid, a reaction reflecting increased nuclear density and protein content within abnormal cells, allowing the colposcopist to identify, map, and, where indicated, biopsy the most abnormal-appearing areas under direct, magnified visualisation.

Fill in the blank: Colposcopy is indicated principally following an abnormal cervical _____ result. Abnormal cervical epithelium becomes visibly whiter, termed _____ change, following application of dilute acetic acid.

5.1.2 Colposcopic technique and findings

Colposcopic examination begins with inspection under normal saline to assess vascular patterns, followed by application of dilute acetic acid and systematic assessment of the transformation zone for acetowhite change, its margins, and any associated abnormal vascular patterns (mosaicism or punctation), and, subsequently, application of Lugol's iodine (Schiller's test), which stains normal, glycogen-containing epithelium brown while abnormal epithelium remains unstained.

Colposcopic findings are classified according to a structured system reflecting the likely severity of underlying dysplasia, with features such as dense, sharply demarcated acetowhite change, coarse mosaicism or punctation, and an abnormal vascular pattern all suggesting more severe underlying disease, guiding both the site selected for biopsy and, in some circumstances, an immediate 'see-and-treat' approach where the colposcopic impression is sufficiently confident.

Fill in the blank: Lugol's iodine application, also called Schiller's test, stains normal, glycogen-containing epithelium _____. Coarse mosaicism, punctation, and an abnormal vascular pattern suggest more _____ underlying disease.

5.1.3 Colposcopy-directed biopsy and management decisions

Colposcopy-directed punch biopsy of the most abnormal-appearing area identified is taken to provide histological confirmation of the grade of cervical intraepithelial neoplasia present, essential before undertaking definitive excisional or ablative treatment in most circumstances, as colposcopic impression alone, while highly informative, does not reliably substitute for histological confirmation in guiding definitive management decisions.

Management following colposcopy is guided by the combination of colposcopic impression, biopsy result, and the woman's individual circumstances, ranging from continued surveillance for low-grade findings likely to regress spontaneously, to excisional treatment such as loop electrosurgical excision procedure for confirmed high-grade disease, with the specific pathway

la-net.com

followed reflecting an appropriately individualised balance between adequately treating significant disease and avoiding overtreatment of lesions likely to resolve without intervention.

Fill in the blank: Colposcopy-directed biopsy provides histological confirmation of the grade of cervical intraepithelial _____ present. Management following colposcopy balances adequately treating significant disease against _____ of lesions likely to resolve.

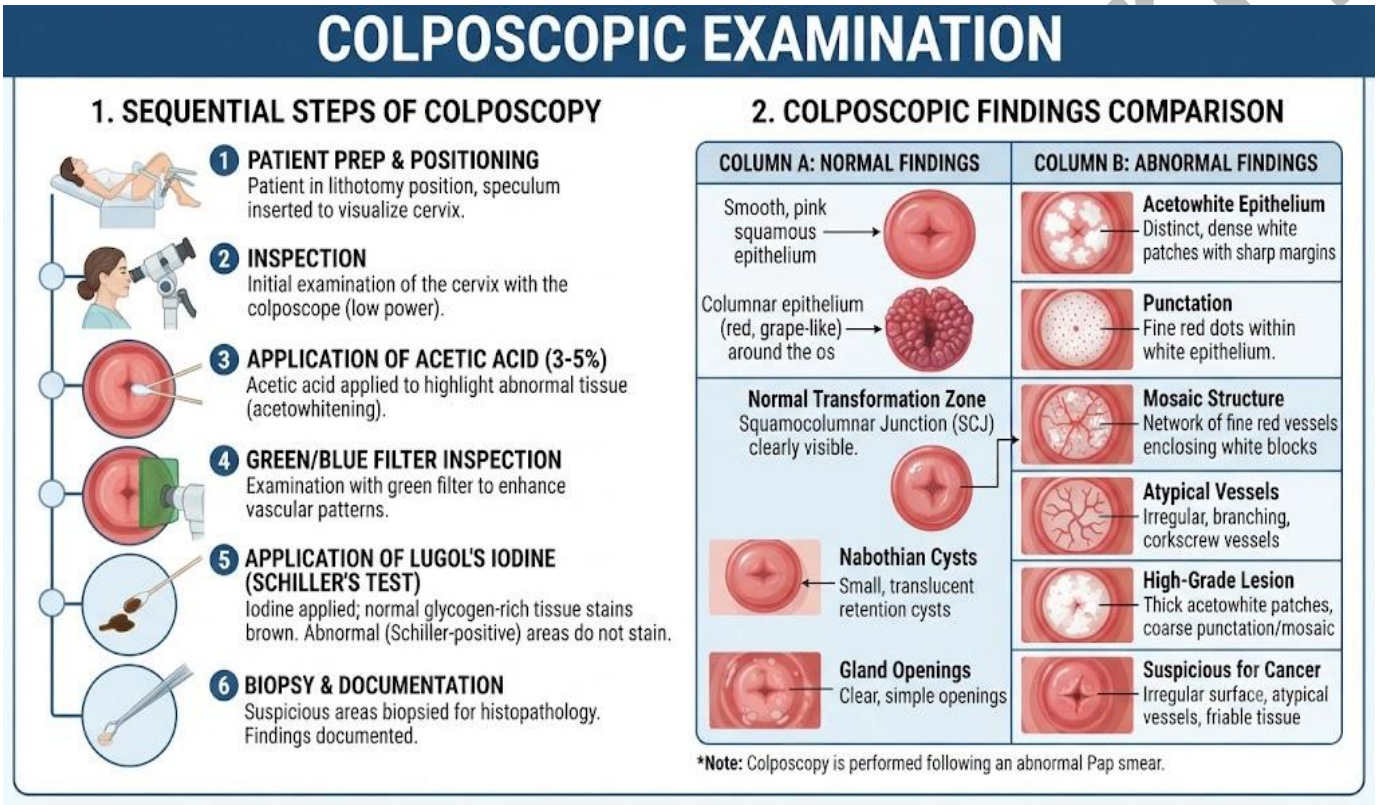

Figure 5.1: Sequential steps and findings of colposcopic examination.

Pilot questions 5.1

- Describe the indications for colposcopy. (Linked to SLO 5.1)
- Explain the principle underlying the use of acetic acid in colposcopy. (Linked to SLO 5.1)
- Describe the sequential steps of a colposcopic examination. (Linked to SLO 5.2)
- Describe the colposcopic features that suggest more severe underlying disease. (Linked to SLO 5.2)
- Explain why histological confirmation by biopsy is generally required before definitive treatment. (Linked to SLO 5.2)

la-NET

5.2 Cryosurgery

5.2.1 Principles and mechanism of cryosurgery

Cryosurgery destroys abnormal tissue by rapid freezing, using a metal probe cooled by a refrigerant gas (typically nitrous oxide or carbon dioxide) applied directly to the tissue surface, causing ice crystal formation within cells, cellular dehydration, and disruption of the cell membrane, ultimately resulting in tissue necrosis and, over subsequent weeks, replacement by new, healthy epithelium as the treated area heals.

A freeze-thaw-freeze technique (two cycles of freezing separated by a thaw period) is generally used to achieve more effective, reliable tissue destruction than a single freeze cycle alone, with the depth and lateral extent of freezing carefully monitored during the procedure to ensure adequate treatment of the abnormal area while minimising unnecessary destruction of surrounding healthy tissue.

Fill in the blank: Cryosurgery causes ice crystal formation, cellular dehydration, and disruption of the cell _____, resulting in tissue necrosis. A freeze-_____-freeze technique achieves more effective tissue destruction than a single freeze cycle.

5.2.2 Indications and technique of cervical cryosurgery

Cervical cryosurgery is indicated for confirmed low-grade cervical intraepithelial neoplasia, or selected high-grade disease where the entire lesion and transformation zone are fully visible and the lesion is small enough for the cryoprobe to adequately cover, making it unsuitable for lesions extending into the endocervical canal beyond direct visualisation, or those with any suspicion of invasive disease, both of which require excisional rather than ablative treatment.

The procedure is generally well tolerated with minimal analgesia required, performed as an outpatient clinic-based procedure with the cryoprobe applied directly to the cervix under direct or colposcopic visualisation, making it a particularly valuable, low-cost, accessible treatment option in resource-limited settings, including many Nigerian gynaecological clinics, where excisional equipment or expertise may be less readily available.

Fill in the blank: Cervical cryosurgery is unsuitable for lesions extending into the _____ canal beyond direct visualisation. Cryosurgery is a particularly valuable, low-cost treatment option in _____-limited settings.

5.2.3 Complications and follow-up after cryosurgery

Complications of cryosurgery are generally minor, including watery vaginal discharge for several weeks as the treated area heals (a normal, expected finding that should be explained to the woman in advance to avoid unnecessary concern), cramping pain during and immediately after the procedure, and, less commonly, infection or delayed bleeding, with cervical stenosis a rare but recognised longer-term complication.

lanetonline.com

Follow-up after cryosurgery includes routine cervical screening at the interval recommended by local protocol to confirm successful treatment and detect any recurrence, with persistent or recurrent abnormality on follow-up screening prompting further colposcopic assessment and consideration of excisional treatment, as cryosurgery, being an ablative rather than excisional technique, does not provide a tissue specimen for histological confirmation of complete treatment.

Fill in the blank: Watery vaginal discharge for several weeks after cryosurgery is a normal, expected finding as the treated area _____. Cryosurgery is an ablative technique and does not provide a tissue specimen for histological confirmation of complete _____.

Aspect	Cryosurgery	Excisional Treatment (LEEP)
Indication	Suitable for small, low-grade CIN lesions confined to ectocervix.	Preferred for high-grade CIN, larger lesions, or when histology is required.
Technique	Freezing cervical tissue with cryoprobe to destroy abnormal cells.	Excision of transformation zone using loop electrosurgical excision procedure.
Specimen Availability	No tissue specimen obtained for histology.	Provides excised tissue for histopathological examination.
Typical Complications	Watery discharge, mild cramping, rare cervical stenosis.	Vaginal bleeding, infection, cervical stenosis, potential impact on future pregnancy outcomes.

Table 5.2: Comparison of cryosurgery and excisional treatment for cervical intraepithelial neoplasia.

Pilot questions 5.2

1. Describe the mechanism by which cryosurgery destroys abnormal tissue. (Linked to SLO 5.3)
2. Explain the purpose of the freeze-thaw-freeze technique in cryosurgery. (Linked to SLO 5.3)
3. Describe the indications and limitations of cervical cryosurgery. (Linked to SLO 5.3)
4. Describe the common complications of cryosurgery and appropriate patient counselling. (Linked to SLO 5.3)
5. Explain why cryosurgery does not provide histological confirmation of complete treatment. (Linked to SLO 5.3)

lanetonline.com

5.3 Hysteroscopy

5.3.1 Indications and principles of hysteroscopy

Hysteroscopy is direct visualisation of the uterine cavity using a narrow, rigid or flexible telescope passed through the cervix, distending the cavity with fluid or, less commonly, gas to allow adequate visualisation, indicated for the investigation of abnormal uterine bleeding (particularly when structural intracavitary pathology is suspected), assessment of the uterine cavity in infertility investigation, and removal of intracavitary lesions such as polyps or submucosal fibroids.

Diagnostic hysteroscopy can frequently be performed in an outpatient clinic setting without general anaesthesia, using a narrow-diameter hysteroscope and, where possible, a vaginoscopic (no-touch) technique that avoids the use of a speculum or cervical instrumentation, considerably improving patient comfort and acceptability compared with traditional hysteroscopic approaches requiring formal cervical dilatation.

Fill in the blank: Hysteroscopy distends the uterine cavity with fluid or, less commonly, _____ to allow adequate visualisation. The vaginoscopic or no-touch technique avoids the use of a speculum or cervical _____.

5.3.2 Diagnostic hysteroscopy technique

Diagnostic hysteroscopy technique involves gentle, careful insertion of the hysteroscope through the cervix into the uterine cavity under continuous visualisation, systematic assessment of the entire cavity including both tubal ostia, the fundus, and all cavity walls, and identification of any structural abnormality such as a polyp, submucosal fibroid, adhesion, or congenital anomaly, with any abnormal area further characterised before deciding whether biopsy or operative intervention is indicated.

Adequate uterine distension throughout the procedure is essential for satisfactory visualisation, achieved using a continuous flow of normal saline in most outpatient settings, with careful monitoring of fluid input and output volumes throughout the procedure, particularly important during longer or operative procedures, given the recognised risk of fluid overload if a significant discrepancy develops between fluid instilled and fluid recovered.

Fill in the blank: Diagnostic hysteroscopy systematically assesses the entire cavity including both tubal _____, the fundus, and all cavity walls. Careful monitoring of fluid input and output reduces the risk of fluid _____ during the procedure.

5.3.3 Operative hysteroscopy and complications

Operative hysteroscopy allows simultaneous treatment of identified pathology, including polypectomy, resection of a submucosal fibroid, division of intrauterine adhesions, and endometrial ablation for heavy menstrual bleeding, typically performed under general or regional

lanetonline.com

anaesthesia given the greater degree of cervical dilatation and instrumentation generally required compared with a purely diagnostic procedure.

Complications of hysteroscopy include uterine perforation (more likely with a distorted or scarred uterine cavity), cervical trauma, infection, and, specifically during operative procedures using electrosurgical instruments, fluid overload or, rarely, gas embolism, all of which require prompt recognition and management should they occur, and appropriate patient selection, technique, and monitoring throughout the procedure meaningfully reduces the incidence of these recognised complications.

Fill in the blank: Operative hysteroscopy allows simultaneous treatment including polypectomy, fibroid resection, and endometrial _____. Uterine perforation is more likely with a distorted or _____ uterine cavity.

Category	Key Details
Indications	Abnormal uterine bleeding, suspected endometrial pathology, evaluation of intrauterine adhesions, infertility assessment.
Operative Procedures	Polypectomy, myomectomy (submucous fibroids), adhesiolysis, endometrial ablation, removal of foreign bodies.
Complications	Uterine perforation, bleeding, infection, fluid overload, anaesthetic risks.

Box 5.3: Indications, operative procedures, and complications of hysteroscopy.

Pilot questions 5.3

1. Describe the indications for hysteroscopy. (Linked to SLO 5.4)
2. Describe the vaginoscopic (no-touch) technique and its advantages. (Linked to SLO 5.4)
3. Describe the technique of diagnostic hysteroscopy. (Linked to SLO 5.4)
4. Describe the procedures that can be performed with operative hysteroscopy. (Linked to SLO 5.5)
5. Describe the complications of hysteroscopy. (Linked to SLO 5.5)

5.4 Laparoscopy

5.4.1 Indications and principles of laparoscopy

laneton line.com

Laparoscopy allows visualisation of the abdominal and pelvic cavity through small incisions using a camera-mounted telescope, with carbon dioxide insufflation creating a working pneumoperitoneum, indicated for both diagnostic purposes (investigation of chronic pelvic pain, suspected endometriosis, or infertility) and operative procedures (ectopic pregnancy management, ovarian cystectomy, and hysterectomy, among many others), offering the advantages of reduced postoperative pain, shorter hospital stay, and faster recovery compared with open surgery.

The pneumoperitoneum created by carbon dioxide insufflation elevates the abdominal wall away from the underlying viscera, creating adequate working space for safe instrument manipulation and clear visualisation, with intra-abdominal pressure carefully monitored and maintained within a safe range throughout the procedure to balance adequate visualisation against the physiological effects of raised intra-abdominal pressure on cardiovascular and respiratory function.

Fill in the blank: Laparoscopy uses carbon dioxide insufflation to create a working _____. Intra-abdominal pressure is carefully monitored to balance visualisation against physiological effects on cardiovascular and respiratory _____.

5.4.2 Laparoscopic technique and entry methods

Laparoscopic entry into the abdominal cavity can be achieved by the Veress needle technique (blind insertion of a spring-loaded needle to establish pneumoperitoneum before primary trocar insertion), the open (Hasson) technique (direct visualisation of fascial and peritoneal layers during entry, generally preferred in patients at higher risk of adhesions), or direct trocar insertion, with the specific method chosen according to patient factors, surgeon experience and preference, and local practice.

Once safe entry and adequate pneumoperitoneum have been established, additional secondary ports are inserted under direct laparoscopic visualisation at positions selected according to the planned procedure, with systematic inspection of the entire abdominal and pelvic cavity performed before proceeding to the specific planned intervention, ensuring any unexpected finding is identified and appropriately addressed or, at minimum, documented.

Fill in the blank: The open (Hasson) entry technique is generally preferred in patients at higher risk of _____. Systematic inspection of the entire abdominal and pelvic cavity should be performed before proceeding to the planned _____.

5.4.3 Complications of laparoscopy and simulation training

Complications of laparoscopy include vascular injury (particularly at the point of initial entry, a genuinely time-critical emergency if a major vessel is injured), visceral injury (bowel, bladder, or ureter), gas embolism (rare but potentially fatal), and complications related to patient positioning or the physiological effects of pneumoperitoneum, with the great majority of serious complications occurring at the point of initial abdominal entry, making this the single most safety-critical step of the entire procedure.

laneronline.com

Simulation-based training using laparoscopic box trainers and virtual reality simulators allows deliberate, repeated practice of fundamental laparoscopic skills, including hand-eye coordination, instrument handling, and basic suturing technique, in a safe, controlled environment before these skills are applied to a real patient, with structured, validated training curricula increasingly recognised as an essential component of safe laparoscopic surgical training, directly reflecting the broader simulation-based approach that runs throughout this entire course.

Fill in the blank: The great majority of serious laparoscopic complications occur at the point of initial abdominal _____, the single most safety-critical step. Laparoscopic box trainers and virtual reality simulators allow deliberate practice of fundamental _____ skills.

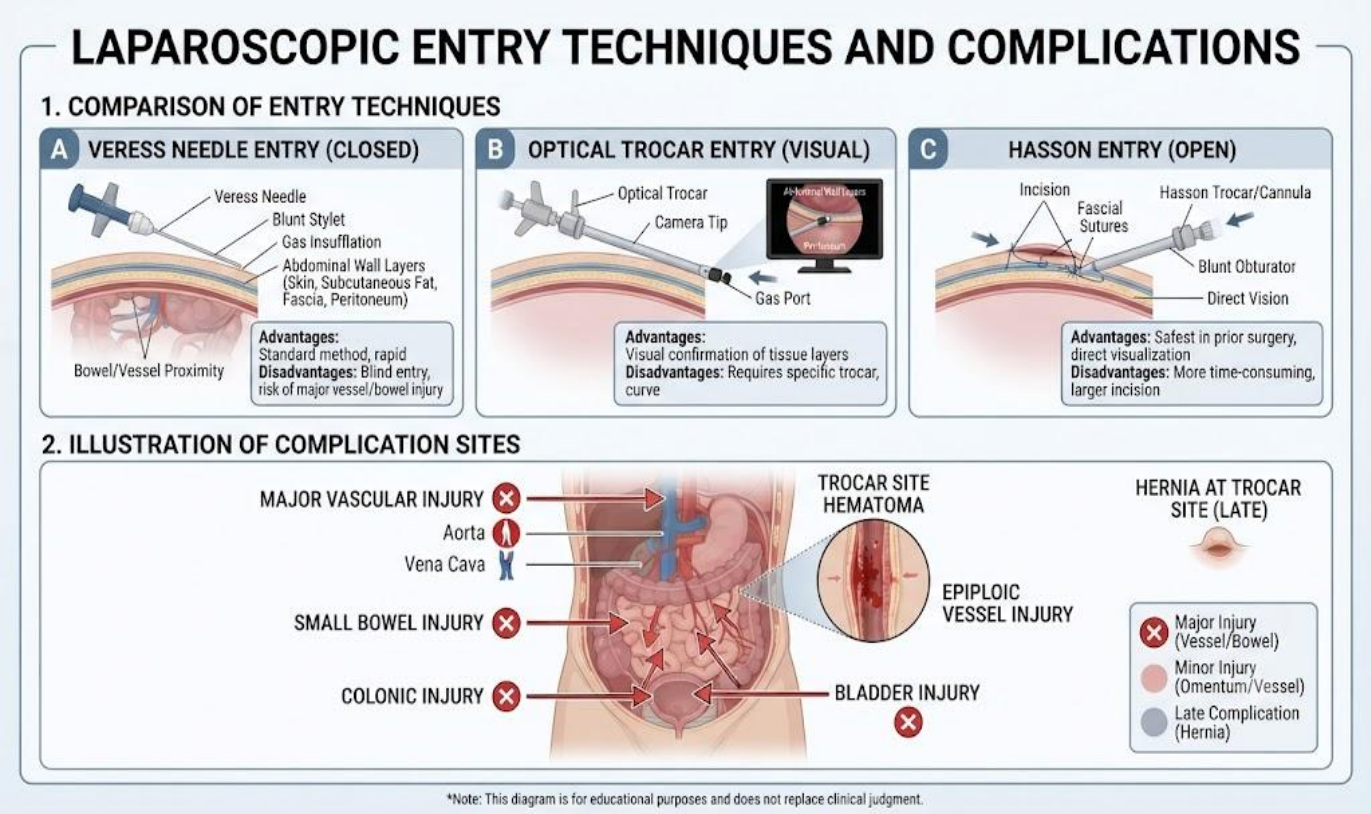

Figure 5.4: Laparoscopic entry techniques and the sites of potential complications.

Pilot questions 5.4

1. Describe the indications for diagnostic and operative laparoscopy. (Linked to SLO 5.6)
2. Explain the purpose and physiological considerations of pneumoperitoneum. (Linked to SLO 5.6)
3. Compare the Veress needle and open (Hasson) laparoscopic entry techniques. (Linked to SLO 5.6)

4. Describe the complications of laparoscopy, particularly those related to initial entry. (Linked to SLO 5.7)
5. Describe the role of simulation-based training in developing laparoscopic surgical skills. (Linked to SLO 5.7)

Series Summary

This Series has covered colposcopy, its indications, technique, and directed biopsy, followed by cryosurgery, its principles, indications, and complications. It went on to examine hysteroscopy, both diagnostic and operative, before concluding with laparoscopy, its technique, complications, and the role of simulation-based training in developing these advanced surgical skills, bringing this course on Gynaecological Clinic and Simulation Training to a close.

You should now be able to describe the indications and technique of colposcopy and directed biopsy, describe cervical cryosurgery, describe diagnostic and operative hysteroscopy, and describe the indications, technique, and complications of laparoscopy, together with the role of simulation training in developing these advanced skills (Linked to SLOs 5.1 to 5.7).

Glossary of Terms

1. **Acetowhite change:** the visible whitening of abnormal cervical epithelium following application of dilute acetic acid during colposcopy.
2. **Colposcopy:** direct, magnified visualisation of the cervix, vagina, and vulva used to further assess an abnormal screening result.
3. **Cryosurgery:** destruction of abnormal tissue by rapid freezing, used to treat confirmed cervical intraepithelial neoplasia.
4. **Hysteroscopy:** direct visualisation of the uterine cavity using a narrow telescope passed through the cervix.
5. **Laparoscopy:** visualisation of the abdominal and pelvic cavity through small incisions using a camera-mounted telescope.
6. **Pneumoperitoneum:** the working space created within the abdominal cavity by carbon dioxide insufflation during laparoscopy.

lanetonline.com

7. **Schiller's test:** application of Lugol's iodine during colposcopy, staining normal epithelium brown while abnormal epithelium remains unstained.
8. **Vaginoscopic (no-touch) technique:** a hysteroscopy technique avoiding the use of a speculum or cervical instrumentation, improving comfort.
9. **Veress needle:** a spring-loaded needle used for blind laparoscopic entry to establish pneumoperitoneum.
10. **Open (Hasson) technique:** a laparoscopic entry technique using direct visualisation of the fascial and peritoneal layers.
11. **Freeze-thaw-freeze technique:** a cryosurgery technique using two freezing cycles separated by a thaw period for more effective tissue destruction.
12. **Endometrial ablation:** an operative hysteroscopic procedure used to treat heavy menstrual bleeding by destroying the endometrial lining.

Concept Check Questions [Series 5]

Objective questions

- Abnormal cervical epithelium becomes visibly whiter, termed _____ change, following application of dilute acetic acid.
- Lugol's iodine application, also called Schiller's test, stains normal, glycogen-containing epithelium _____.
- Cervical cryosurgery is unsuitable for lesions extending into the _____ canal beyond direct visualisation.
- The vaginoscopic or no-touch hysteroscopy technique avoids the use of a speculum or cervical _____.
- Laparoscopy uses carbon dioxide insufflation to create a working _____.

Short-answer questions

1. Explain why histological confirmation by biopsy is generally required before definitive treatment. (Linked to SLO 5.2)

laNETonline.com

2. Explain why cryosurgery does not provide histological confirmation of complete treatment. (Linked to SLO 5.3)
3. Describe the procedures that can be performed with operative hysteroscopy. (Linked to SLO 5.5)
4. Compare the Veress needle and open (Hasson) laparoscopic entry techniques. (Linked to SLO 5.6)
5. Describe the role of simulation-based training in developing laparoscopic surgical skills. (Linked to SLO 5.7)

Long-answer questions

6. Describe the indications, technique, and findings of colposcopy, and the role of directed biopsy. (Linked to SLO 5.1, SLO 5.2)
7. Describe the principles, technique, and complications of cervical cryosurgery. (Linked to SLO 5.3)
8. Describe the indications, technique, and complications of diagnostic and operative hysteroscopy. (Linked to SLO 5.4, SLO 5.5)
9. Describe the indications, technique, and complications of laparoscopy. (Linked to SLO 5.6, SLO 5.7)
10. Describe the role of simulation-based training across colposcopy, hysteroscopy, and laparoscopy. (Linked to SLO 5.7)

Answers to Concept Check Questions [Series 5]

Objective questions

11. Acetowhite.
12. Brown.
13. Endocervical.
14. Instrumentation.
15. Pneumoperitoneum.

laetonline.com

Short-answer questions

16. Colposcopic impression alone does not reliably substitute for histological confirmation in guiding definitive management decisions.
17. Cryosurgery is an ablative technique that destroys tissue in place rather than removing a specimen for laboratory analysis.
18. Polypectomy, resection of a submucosal fibroid, division of intrauterine adhesions, and endometrial ablation.
19. The Veress needle is blind insertion before pneumoperitoneum; the open technique uses direct visualisation, preferred with higher adhesion risk.
20. It allows deliberate, repeated practice of fundamental skills in a safe environment before application to a real patient.

Long-answer questions

21. **Basic response:** Colposcopy uses acetic acid and iodine to identify abnormal cervical epithelium, with directed biopsy providing histological confirmation before definitive treatment.

Value-added response: Colposcopic impression alone does not reliably substitute for histology, so biopsy remains essential before excisional or ablative treatment in most cases.

22. **Basic response:** Cryosurgery destroys abnormal cervical tissue by freezing, suitable for fully visible lesions, with expected discharge but generally minor complications.

Value-added response: Being ablative rather than excisional, cryosurgery provides no tissue specimen, making follow-up screening essential to confirm successful treatment.

23. **Basic response:** Hysteroscopy visualises the uterine cavity for diagnosis or treatment of intracavitary pathology, with operative procedures generally requiring anaesthesia.

Value-added response: Laparoscopy carries the greatest complication risk at initial entry, making simulation-based training in fundamental skills a genuinely essential preparation.

laretonline.com

Answers to Pilot Questions [Series 5]

Part 5.1

1. Following an abnormal cervical screening result, and investigation of post-coital bleeding or a visible cervical lesion.
2. Abnormal, dysplastic epithelium reacts differently to acetic acid, becoming visibly whiter than normal epithelium.
3. Saline inspection, acetic acid application and acetowhite assessment, then Lugol's iodine (Schiller's test).
4. Dense, sharply demarcated acetowhite change, coarse mosaicism or punctation, and abnormal vascular pattern.
5. Colposcopic impression alone does not reliably substitute for histology in guiding definitive management decisions.

Part 5.2

6. Rapid freezing causes ice crystal formation, cellular dehydration, and membrane disruption, leading to tissue necrosis.
7. It achieves more effective, reliable tissue destruction than a single freeze cycle alone.
8. Indicated for confirmed low-grade or selected fully visible high-grade disease; unsuitable for endocervical extension or suspected invasion.
9. Watery discharge for several weeks (expected), cramping pain, and rarely infection, bleeding, or cervical stenosis.
10. Cryosurgery is ablative, destroying tissue in place rather than providing a specimen for histological analysis.

Part 5.3

11. Investigation of abnormal uterine bleeding, assessment of the cavity in infertility, and removal of intracavitary lesions.
12. It avoids a speculum or cervical instrumentation, considerably improving patient comfort compared with traditional approaches.

laNETonline.com

13. Gentle insertion under continuous visualisation, systematic assessment of the cavity, tubal ostia, and fundus.
14. Polypectomy, submucosal fibroid resection, division of adhesions, and endometrial ablation.
15. Uterine perforation, cervical trauma, infection, and, in operative procedures, fluid overload or gas embolism.

Part 5.4

1. Diagnostic uses include chronic pelvic pain, endometriosis, and infertility investigation; operative uses include ectopic pregnancy and cystectomy.
2. Pneumoperitoneum creates working space for visualisation, with pressure monitored to balance visualisation against physiological effects.
3. Veress needle is blind insertion; open Hasson technique uses direct visualisation, preferred with higher adhesion risk.
4. Vascular and visceral injury, particularly at entry, gas embolism, and complications related to pneumoperitoneum or positioning.
5. It allows deliberate, repeated practice of fundamental skills in a safe environment before application to real patients.

References and Attributions [Series 5]

Textual References

1. Hoffman, B. L., Schorge, J. O., Halvorson, L. M. et al. (2020). Williams Gynecology (4th ed.). McGraw Hill.
2. World Health Organization (2021). WHO Guideline for Screening and Treatment of Cervical Pre-Cancer Lesions for Cervical Cancer Prevention (2nd ed.). WHO Press.
3. Royal College of Obstetricians and Gynaecologists (2008). Green-top Guideline No. 49: Preventing Entry-Related Gynaecological Laparoscopic Injuries. RCOG Press.
4. American Association of Gynecologic Laparoscopists (2012). AAGL Practice Report: Practice Guidelines for the Diagnosis and Management of Endometrial Polyps. Journal of Minimally Invasive Gynecology, 19(1), 3 to 10.

laNETonline.com

Figures, Plates, Tables, and Boxes

1. Figure 5.1: Sequential steps and findings of colposcopic examination. AI-generated using the prompt: "Create a professional medical diagram titled Colposcopic Examination, showing the sequential steps and comparing normal and abnormal colposcopic findings. Clean clinical educational diagram style."
2. Table 5.2: Comparison of cryosurgery and excisional treatment for cervical intraepithelial neoplasia. AI-generated using the prompt: "Create a clean reference table titled Cryosurgery versus Excisional Treatment for CIN, comparing indication, technique, specimen availability, and complications. Simple clinical reference table style with outside border."
3. Box 5.3: Indications, operative procedures, and complications of hysteroscopy. AI-generated using the prompt: "Create a simple single-column reference box with an outside border titled Hysteroscopy: Indications, Procedures, and Complications, listing key points for each category. Clinical reference box style."
4. Figure 5.4: Laparoscopic entry techniques and the sites of potential complications. AI-generated using the prompt: "Create a professional medical diagram titled Laparoscopic Entry Techniques and Complications, comparing entry methods and illustrating complication sites. Clean clinical educational diagram style."

lanetonline.com